




# **EMERGENCY ENDOSCOPY**



**Kristine J. Krueger M.D.  
Professor and Chief of Gastroenterology,  
Hepatology and Nutrition,  
University of Louisville, Kentucky**

# Emergency Endoscopy Applications

- Upper and Lower GI bleeding
- Obstructed esophagus
- Foreign Body Removal
- Caustic Ingestions


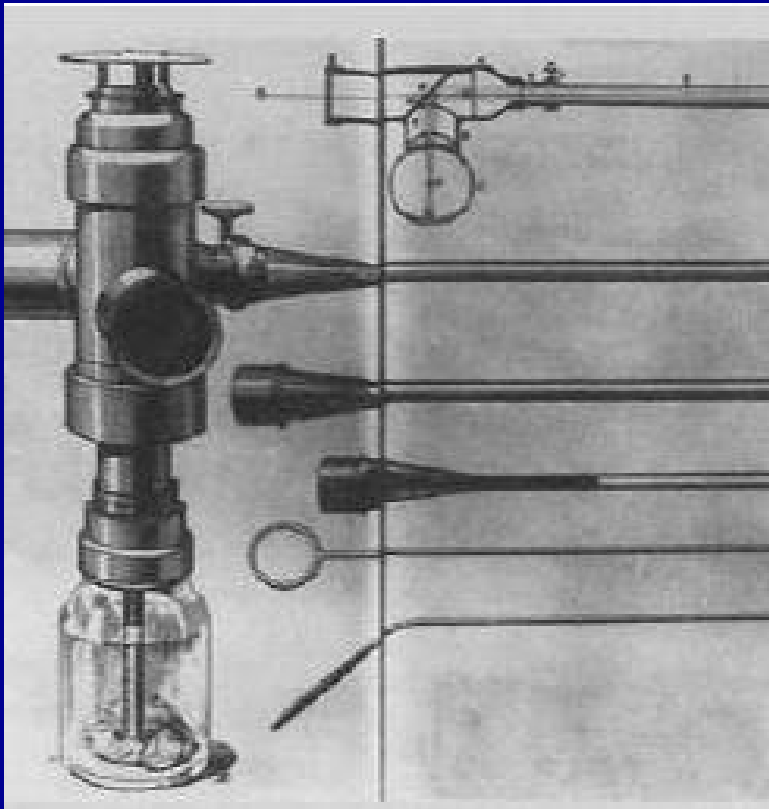


**GI Bleeding can be scary,  
unless you are prepared!**






# History of Endoscopy



Kussmaul (gastroscope) 1868, Thomas Edison 1878 (light), Hoffman 1911 (lenses), Curtiss and Hirschowitz (flexible fiberoptic endoscope) in 1958, first polypectomy in 1969

# Emergency Endoscopy Preparation

## Specialized equipment

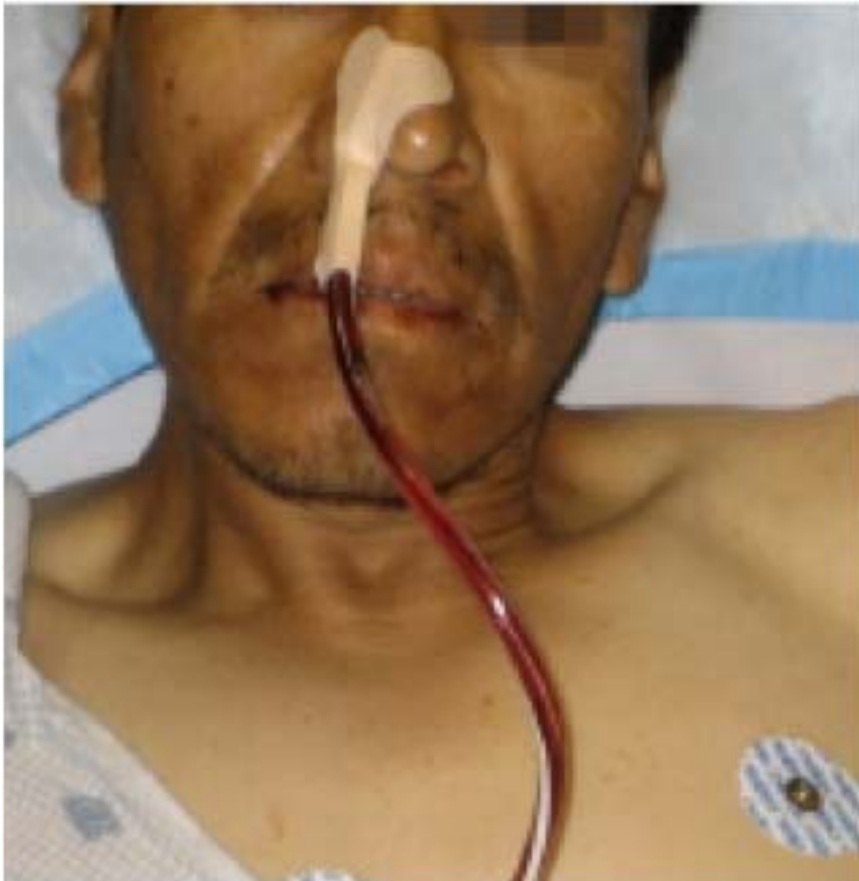

## Trained Personnel

- Endoscopist
- Nurse for conscious sedation
- Technician to hand accessories



# Patient Preparation



- Adequate IV access
- Volume resuscitate
- Type and Cross match
- Abdominal and Chest plain films
- Informed consent

# Utility Of NG Tube Aspiration

- **50%** duodenal lesion bleedings have a **false negative** aspirate
- **14%** with clear or bile aspirate have high risk lesions **misleading information**
- **42%** with a blood in the NG tube have stopped bleeding or have a clean based ulcer **false positive**

**NG Tube aspiration has limited diagnostic and prognostic value, and does not change management**

# **Mortality is Predictable Based on Clinical Exam**

<b>Coffee Ground Emesis</b>  <b>Melena</b>	<b>Hematemesis</b>  <b>Melena</b>
<b>Dark NG aspirate</b>  <b>Maroon or Red Blood Per Rectum</b>	<b>Red/Red</b>  <b>10% mortality</b>



# *UGI Bleed Score – Rockall 1996*

## **Rebleeding & Mortality Risk**

<b>*</b>	<b>0</b>	<b>1</b>	<b>2</b>	<b>3</b>
<b>Age</b>	<b>&lt;60</b>	<b>60-79</b>	<b>&gt;80</b>	
<b>Vitals</b>	<b>SBP&gt;100 P&lt;100</b>	<b>SBP&gt;100 P&gt;100</b>	<b>SBP&lt;100</b>	
<b>Co-morbidity</b>	<b>None</b>		<b>CHF CAD</b>	<b>Renal failure Liver failure Cancer w/mets</b>
<b>Diagnosis</b>	<b>MW tear</b>	<b>All other Dx</b>	<b>UGI cancer</b>	
<b>Stigmata</b>	<b>Clean base Flat spot</b>	<b>Visible vessel Adherent clot Spurting vessel</b>		

**\*Risk of rebleeding and mortality increases with score: Low (0-2), Intermediate (3-4), High (5-10)**

# The Blatchford Score

■ BUN mmol/L	■ 2-6
■ Hemoglobin g/L	■ 1-6
■ SBP	■ 1-3
■ Pulse > 100	■ 1
■ Melena	■ 1
■ Syncope	■ 2
■ Liver disease	■ 2
■ Cardiac Failure	■ 2

**A score of zero accurately predicts low risk patients who can be managed as outpatients**

# AIM65 GI Bleeding score

## Predictable and Practical

### Risk Factor

■ Albumin <3.0	1
■ INR > 1.5	1
■ Altered mental status	1
■ SPB > 90mm Hg	1
■ Age > 65	1

### Mortality

■ 0	0%
■ 1	0.9%
■ 2	7.4%
■ 3	42%
■ 4	75%
■ 5	100%

Scoring Assists with level of care and timing for endoscopy  
Hyett, et al, Gastrointestinal Endosc 2013;77:551-7



# **Indicators of High Risk Lesions Significant or Ongoing Bleeding**

- **Presentation with shock**
- **Age >60**
- **Hemoglobin <8.0**
- **Hematemesis, High volume Hematochezia**
- **Witnessed or history of continuous bleeding**
- **History of Liver Cirrhosis, Coagulopathy, Anticoagulant or Antiplatelet Use**

# Bleeding Gastroesophageal Varices

- Present in 50% cirrhotics
- Bleeding if Portal Pressure  $>12\text{mmHg}$
- Mortality from variceal bleed = 30% / episode
- Size does matter
  - If small bleeding risk = 10% / yr
  - If large bleeding risk = 30% / yr
  - Re-bleeding rate of large varices 70% / 3mo

# Blood loss is variable depending on source

## Upper GI Bleeding

- 35% present with shock
- 65% require transfusion
- 30% require intervention to stop bleeding

## Lower GI Bleeding

- 19% present with shock
- 36% require transfusion
- >90% spontaneously stop bleeding

*The goal of therapy is to prevent end-organ ischemic damage  
Achieved by stopping ongoing blood loss as soon as possible*



# Conditions Associated with Severe GI Bleeding

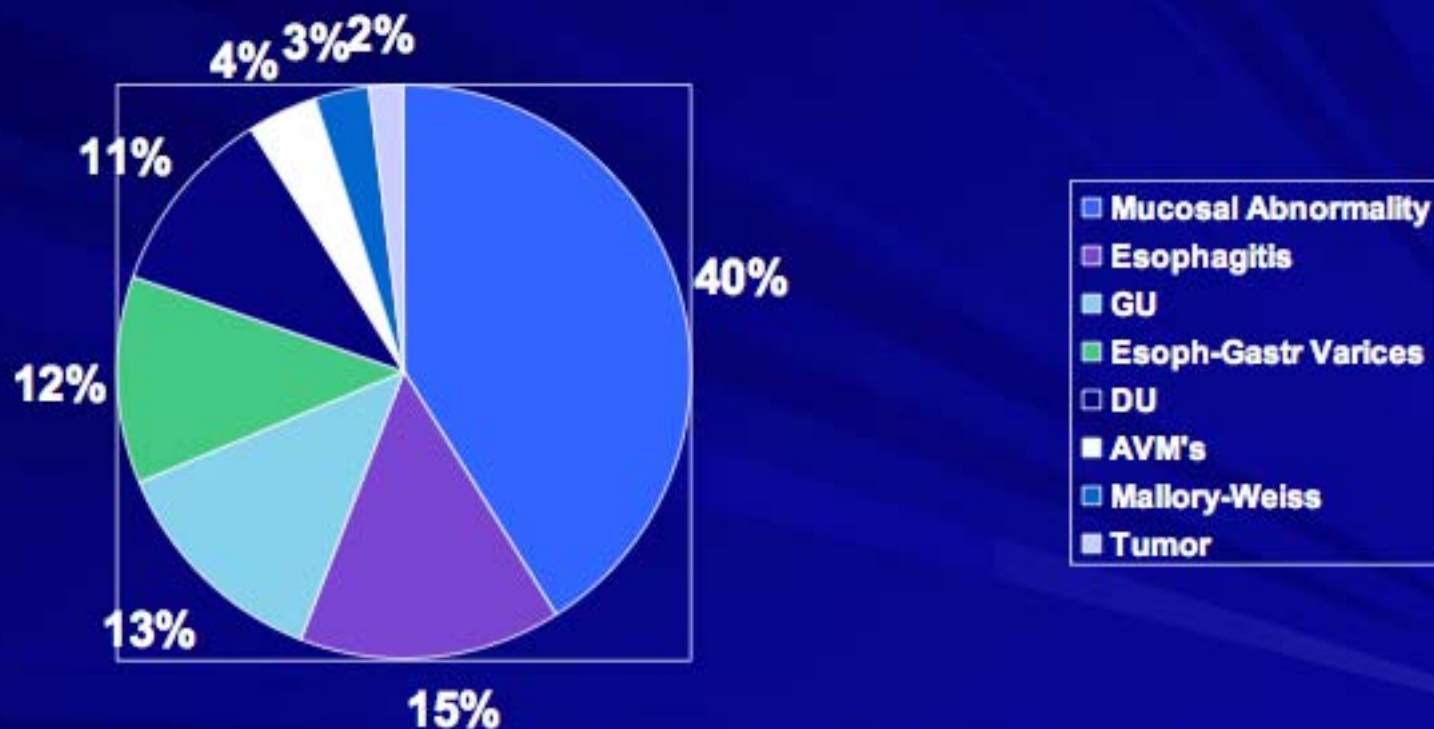
- **Coagulopathy or anticoagulant medications**
- **Portal hypertenion/cirrhosis**
  - **Varices**
- **Arteriolar bleeding**
  - **Dieulafoy lesion proximal stomach**
  - **Ulcer on posterior duodenal bulb**
  - **AV fistula erosion**

# Demographics: GI Bleeding

- Upper source: 65-80%
- 350,000 U.S. hospital admissions year
- Cost burden average \$8,000 per admission
- Gastric ulcer incidence has increased due to NSAID use and *Helicobacter pylori* infection
- Increased use of warfarin, aspirin, clopidogrel due to atherosclerotic disease
- 40% > 60 yrs old, more diverticuli and AVM's
- Viral hepatitis and fatty liver/cirrhosis increasing

# Causes of UGI Bleeding

Boonpongmanee S et al. Gastrointest Endosc 2004;59:788

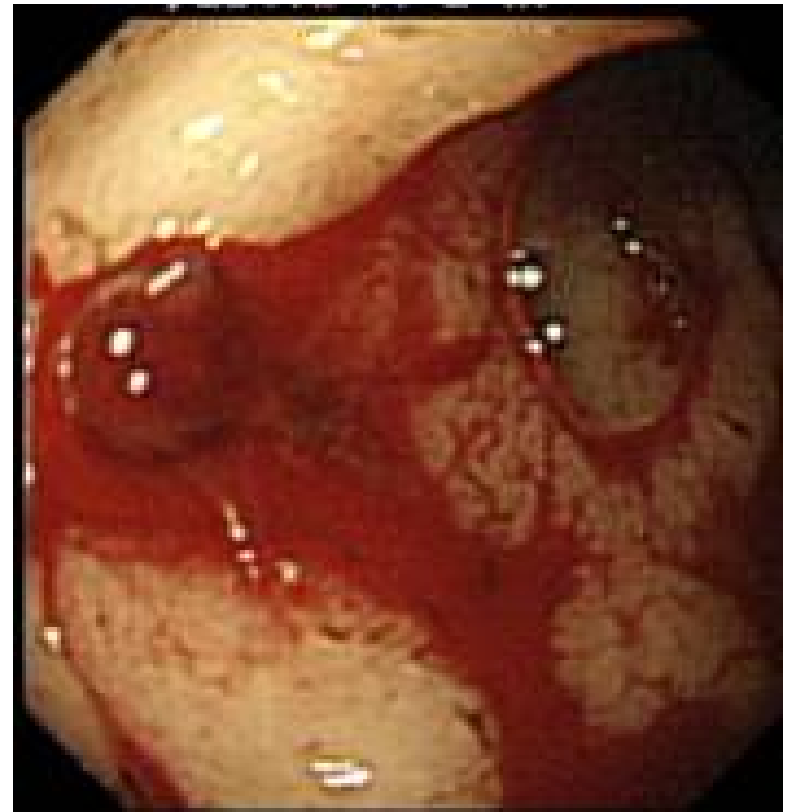
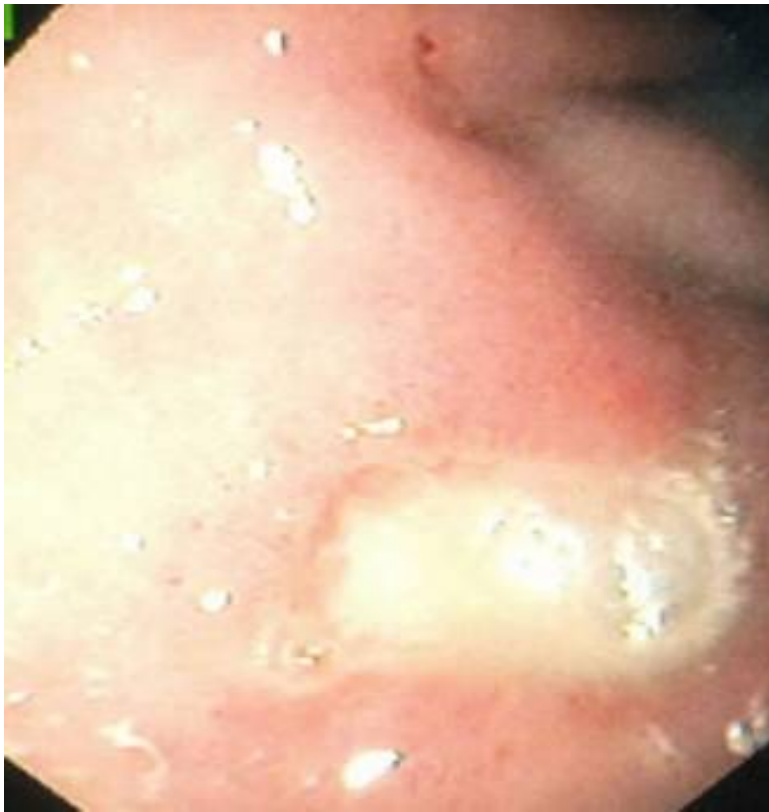



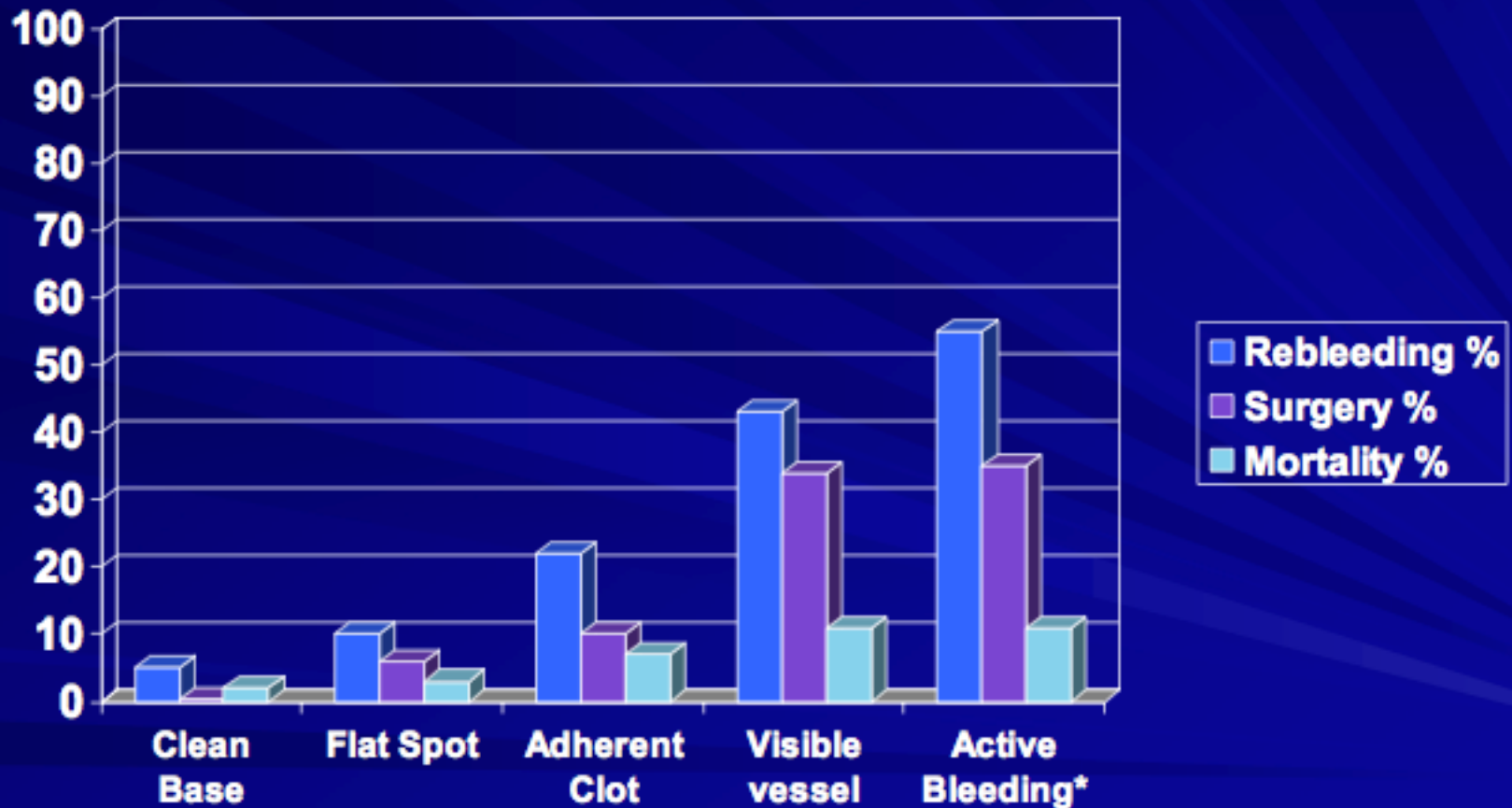
# Causes of Lower GI Bleeding

- 40% Diverticuli
- 30% vascular ectasias
- 10-20% colitis
- 15% neoplasia
- 10% anorectal lesions
- 11% upper GI bleed mistaken as lower
- 9% small bowel source (AVM, aphthous ulcer)

# Prognosis Is Related To Endoscopic Findings



# Prognosis by Endoscopic Stigmata of Recent Hemorrhage

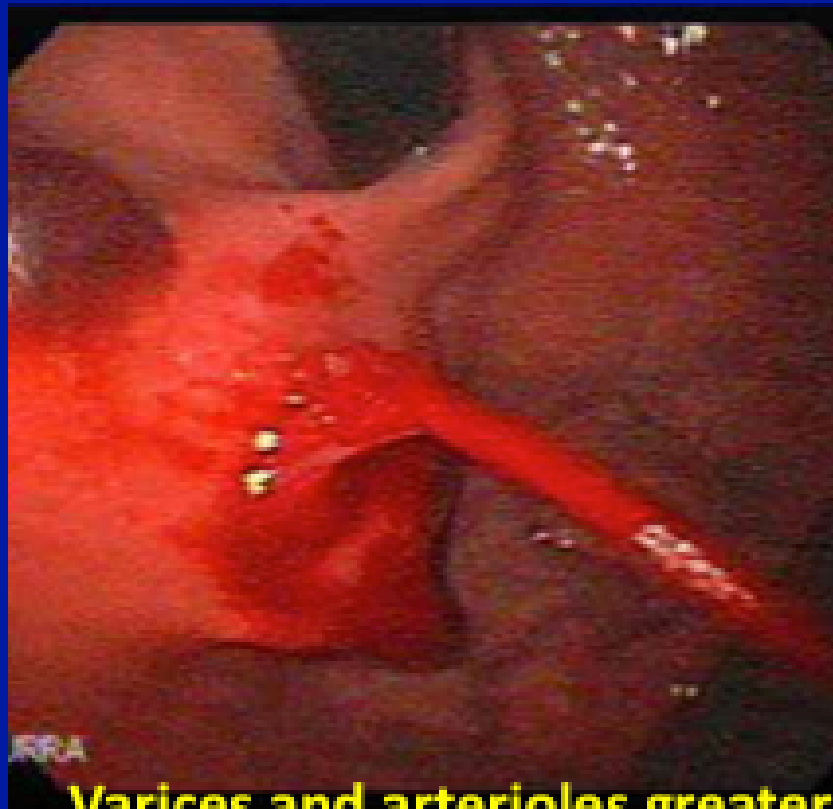

\*Oozing, without adherent clot nor visible vessel, has low risk of re-bleeding after endoscopic therapy, and its re-bleeding rate is not affected by high-dose IV PPI. OK to give PO PPI.

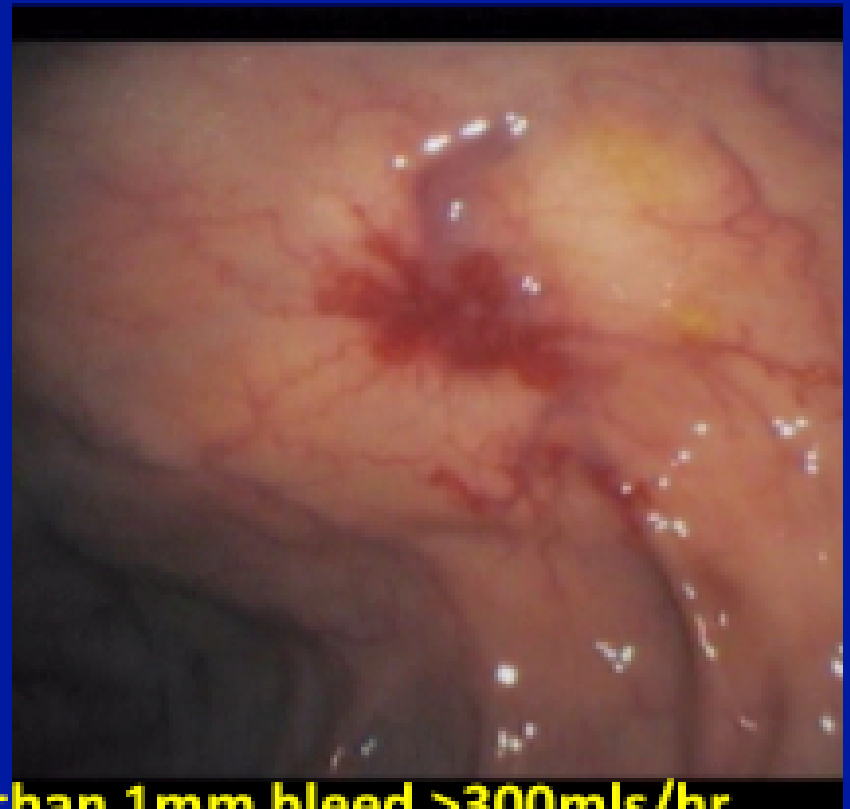

# Pathophysiology of Bleeding Lesions: Big Vessels Bleed More

Endoscopy for Treatment



Endoscopy for Diagnosis



**Varices and arterioles greater than 1mm bleed >300mls/hr**

# Case One - Hematemesis

- 43 year old painter with sudden nausea and bright red blood hematemesis is brought by car to your emergency department. He admits to drinking a six pack of beer daily. He takes no medications.
- He looks pale, SBP is 100, pulse is 105, abdomen is soft with hyperactive bowel sounds. He has a few spider angiomas on his chest
- He asks for a bed pan and passes a large amount of maroon stool, then he passes out.

*How do you manage this case?*

# Case Two - Rectal Bleeding

- 68 yr old frail female brought by ambulance from the nursing home after falling while ambulating to the bathroom. Medicines include aspirin, clopidogrel (post stroke) and ibuprofen for arthritis. She reports occasional dark stools, and occasional red blood per rectum.
- She is pale, mildly confused, and tachypneic , with SPB 105 heart rate 98 and irregular. Her abdominal exam reveals tenderness in the left low quadrant without rebound, a rectal exam reveals dark brown stool mixed with fresh blood
- Hemoglobin is 6.4 with MCV 70. Creatinine is 2.4

*How do you manage this case?*

# Management of GI Bleeding

## ■ Resuscitate

## ■ Resuscitate

## ■ Resuscitate!!!!

- Airway, Breathing
  - Intubation, oxygen
- Circulation
  - IV access two peripheral large bore or central line
  - Normal saline, ringers lactate
  - Type and Cross match for packed cell transfusion
  - Fresh frozen plasma, platelets, cryoprecipitate



# How Much Blood is Enough?

- Maximum tissue oxygen extraction estimates hemoglobin 8.0 is sufficient (Fick principle)
- Transfusion risk increases with each unit of blood
- Volume expansion increases the pressure in bleeding vessels (promotes ongoing blood loss or re-bleeding)
- Exceptions include patients with CHF (low cardiac reserve), coronary ischemia (higher demand) – transfuse to Hgb 10 or until symptoms abate.

# Restrictive (Hb 7-8) vs Liberal (Hb 9-10) Transfusion in Acute Variceal Bleed

Colomo A, et al. AASLD Abstr 210, 2009

## ■ Study:

- Prospective, randomized, in cirrhosis with acute variceal bleed.

## ■ Intervention:

- **a) Restrictive:** transfuse to keep Hb 7-8 g/L.
- **b) Liberal:** transfuse to keep Hb 9-10 g/L.

## ■ Measurements:

- hemodynamics within 48 h and 2-4 d later

## ■ RESULTS:

### ■ Therapeutic failure:

- higher in liberal group.

### ■ 42 d survival without bleeding:

- worse in liberal group.

### ■ Patients in liberal group had elevation in MAP, HVPG, SVR, and decrease in cardiac output.

### ■ Patients in restrictive group did not have hemodynamic changes.

# **Pharmacotherapy for ANY Significant GI Bleeding**

**Octreotide 50mcg bolus then 50mcg/hour  
(decreases glucagon/opposes vasodilation)**

- **Superior to placebo in randomized controlled trials for all causes portal hypertension**
  - **Reduced transfusion, re-bleeding, improved mortality**
- **Case series with improved outcomes for peptic and duodenal ulcer**
- **Case series with decreased transfusion need in diverticuli and AVM's**

# Pharmacotherapy for Upper GI Bleeding

- Proton pump inhibitor (PPI) for 3 days decreases re-bleeding in patients with ulcers requiring endoscopic intervention (6.7% vs. 22% placebo) also reduces need for surgery

Optimal pH 7 for plt function/clot adherence

- In H pylori (+) peptic ulcer, antibiotic eradication decreases ulcer recurrence:
  - DU from 67% to 6%
  - GU from 59% to 4%



# **Antibiotics for GI Bleeding**

**Ceftriaxone 1gm/d or Norfloxacin 400mg BID for cirrhotic patients with GI bleeding:**

- **Decreased mortality by 25%**
- **Reduced infection risk by 60%**
- **Decreases re-bleeding rate by 56%**
- **Decreases transfusion needs (2.7 vs. 0.7 units)**

**Erythromycin 250mg IV 30 minutes before EGD**

- **Improves visualization and treatment of lesions**

# Endoscopy in Acute MI

- Patients with GI bleeding leading to acute MI are more likely to require endoscopic or interventional therapy
- The benefit of urgent endoscopy before heart catheterization in patients with significant GI bleeding and acute MI reduced overall deaths from 600 to 97 per 10,000 patients
- Endoscopy is not beneficial in patients with acute MI and occult blood loss

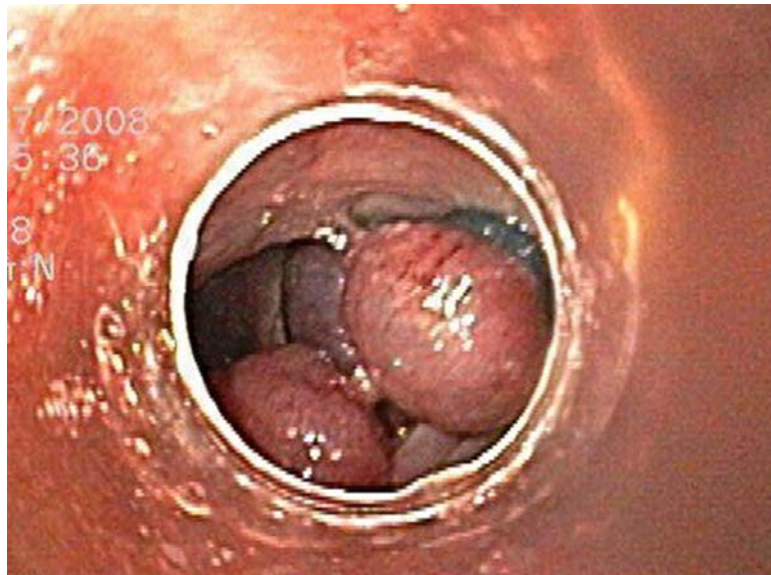
# **Management of Clopidogrel and Warfarin in GI bleed**

- **Main goal is stop bleeding as soon as possible**
- **Evaluate**
  - **Risk of continuous/recurrent bleeding**
  - **Severity of hemorrhage**
  - **Risk of thrombosis/acute coronary event**
- **Consult Cardiology or Neurology**
  - **Lovanox or heparin may be indicated**
  - **Reversal of anticoagulation may be contraindicated**

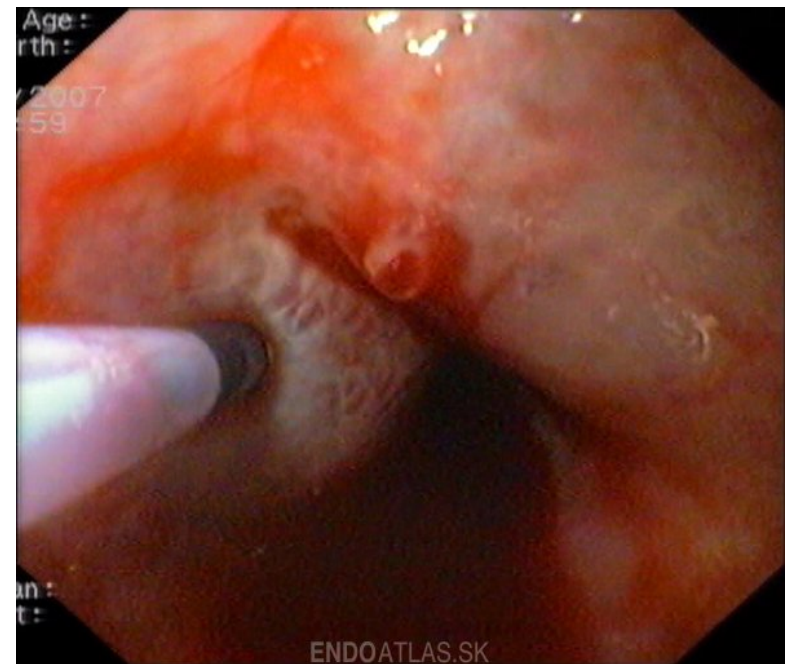


# Endoscopy for Upper GI Bleeding

## Band Ligation



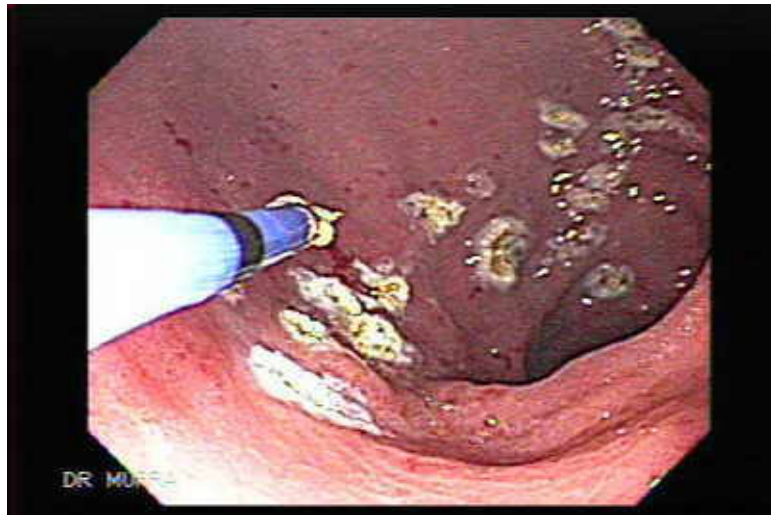
## Sclerotherapy



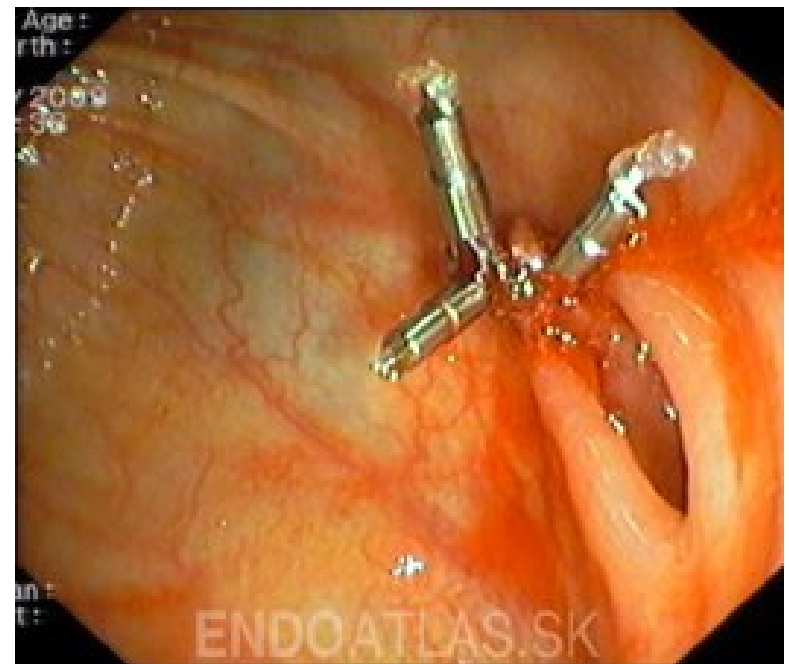


# Endoscopy for Lower GI Bleeding

## Argon plasma



## Endoscopic clipping



# **Therapeutic Upper Endoscopy Improves Outcomes**

**Multiple Randomized controlled clinical trials**

**“endotherapy” = inject, band, clip, cauterize, show significantly improved outcomes than medical treatment alone**

- **Reduced hospital length of stay**
- **Reduced need for transfusions or surgery**
- **Reduced rate of re-bleeding**
- **Reduced mortality (compared to non-intervention)**

# Upper GI Bleeding Outcomes Have Not Changed in Many Decades.....

Despite improved medical and surgical care, overall mortality remains unacceptably high:

- 6-10% non-variceal causes
- 33% variceal hemorrhage

*Are the patients different? YES (older, anti-plt therapy)*  
*Could improved techniques have major impact?*



**Timing is critical**





# Timing to Endoscopy and Outcomes in Upper Gastrointestinal Bleeding

Sarin, N. Can J Gastroenterol Vol 23 No 7, July 2009

- Retrospective chart review
- 502 pts, 375 non-variceal, 10% variceal
- Timing <6 hours (early) vs. 6-24 hrs vs. >24 hrs
  - No difference in length of stay
  - No difference in need for surgery
  - No difference in transfusion requirements
  - No difference in mortality

*Patients were 3.6 x more likely to require surgery or die if endoscopy done within 6 hours compared to >24 hours*

*Conclusion: Time to endoscopy was not associated with better outcomes and most patients could be effectively managed within 24 hours*

# Admission Time is Associated with Outcome of Upper GI Bleeding

N.L. de Groot, et al, Aliment Pharmacol Ther 2012;36:477-484

- 9% mortality on weekends vs. 3% weekdays
- Patients admitted during the evening had a significantly longer time to endoscopy
- Multicenter Prospective cohort study, 571 patients, 8 hospitals
- Only independent predictor for poorest outcome was massive hematemesis and circulatory collapse

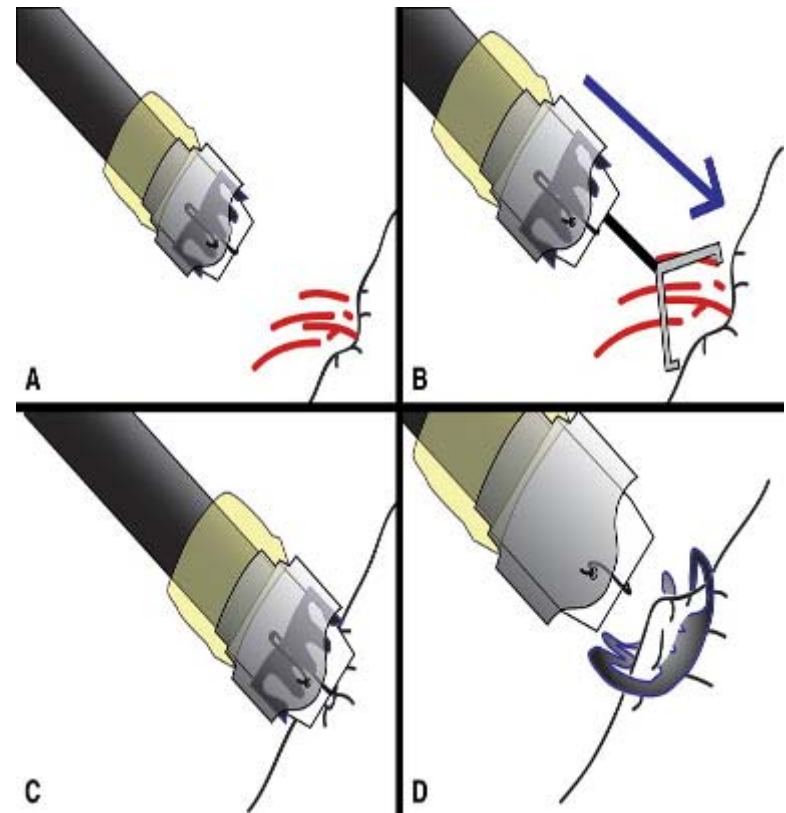
*No difference in Quality of Care, Attributed findings to differences in patients!*

# Poor outcomes Associated with Massive Ongoing Blood Loss



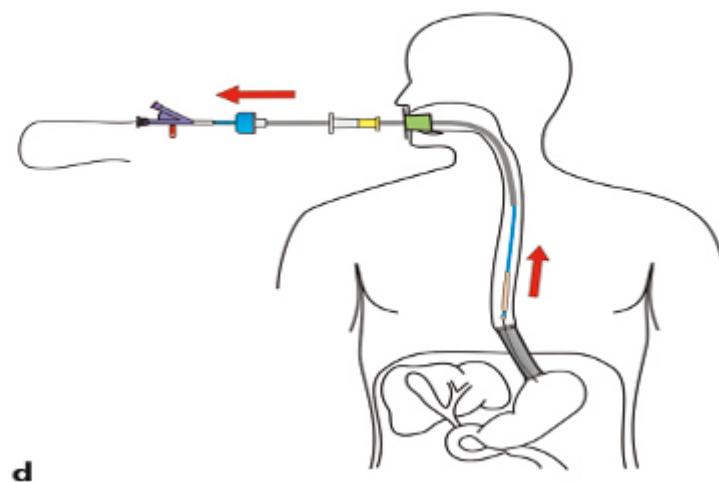
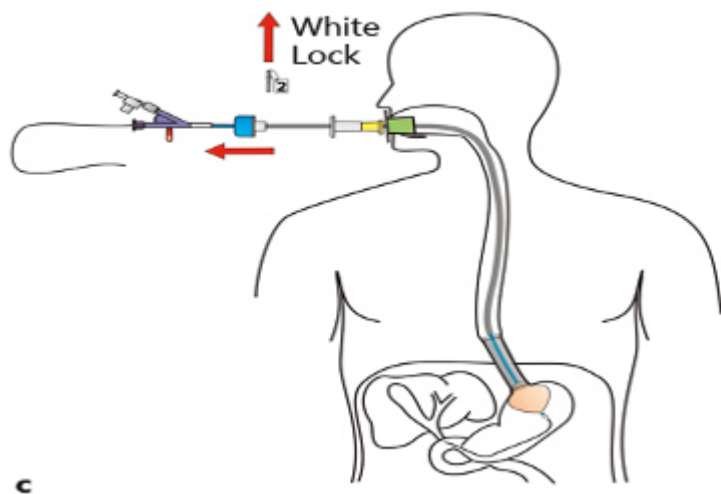
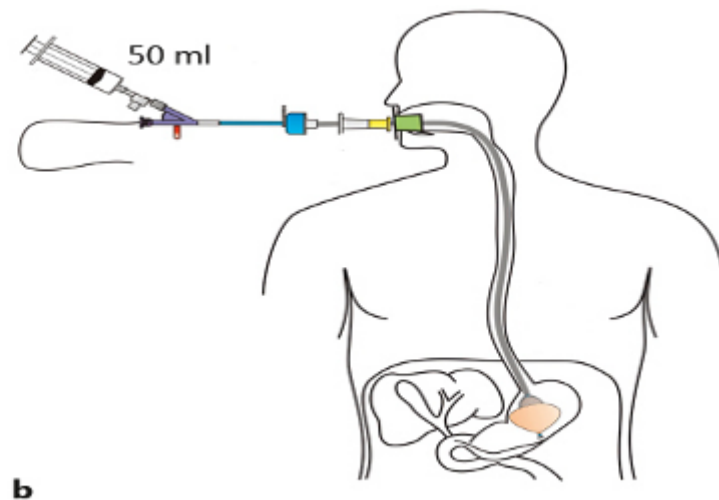
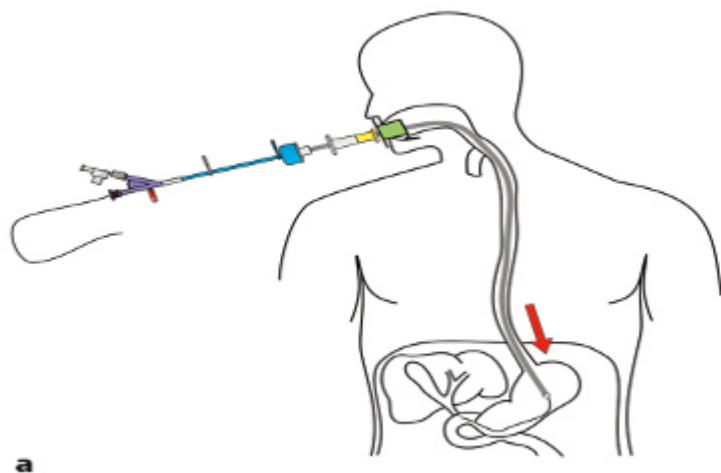
# Emerging Technologies for Endoscopic Hemostasis

- Hemostatic Sprays (hemospray) and Ankaferd Blood Stopper
- Mechanical Devices-Over the Scope Clip (OTSC)
- Self Expanding Metal Stents for Esophageal Variceal Bleeding, SX-Ella Danis stent
  - Removable, fully covered
  - Can be placed without endoscopy or fluoroscopy






## Fully Covered Self Expandible Metal Stent (SEMS) SX-Ella Danis Stent (Czech Republic)



# **Hemospray: A New Approach to Acute GI Bleeding**

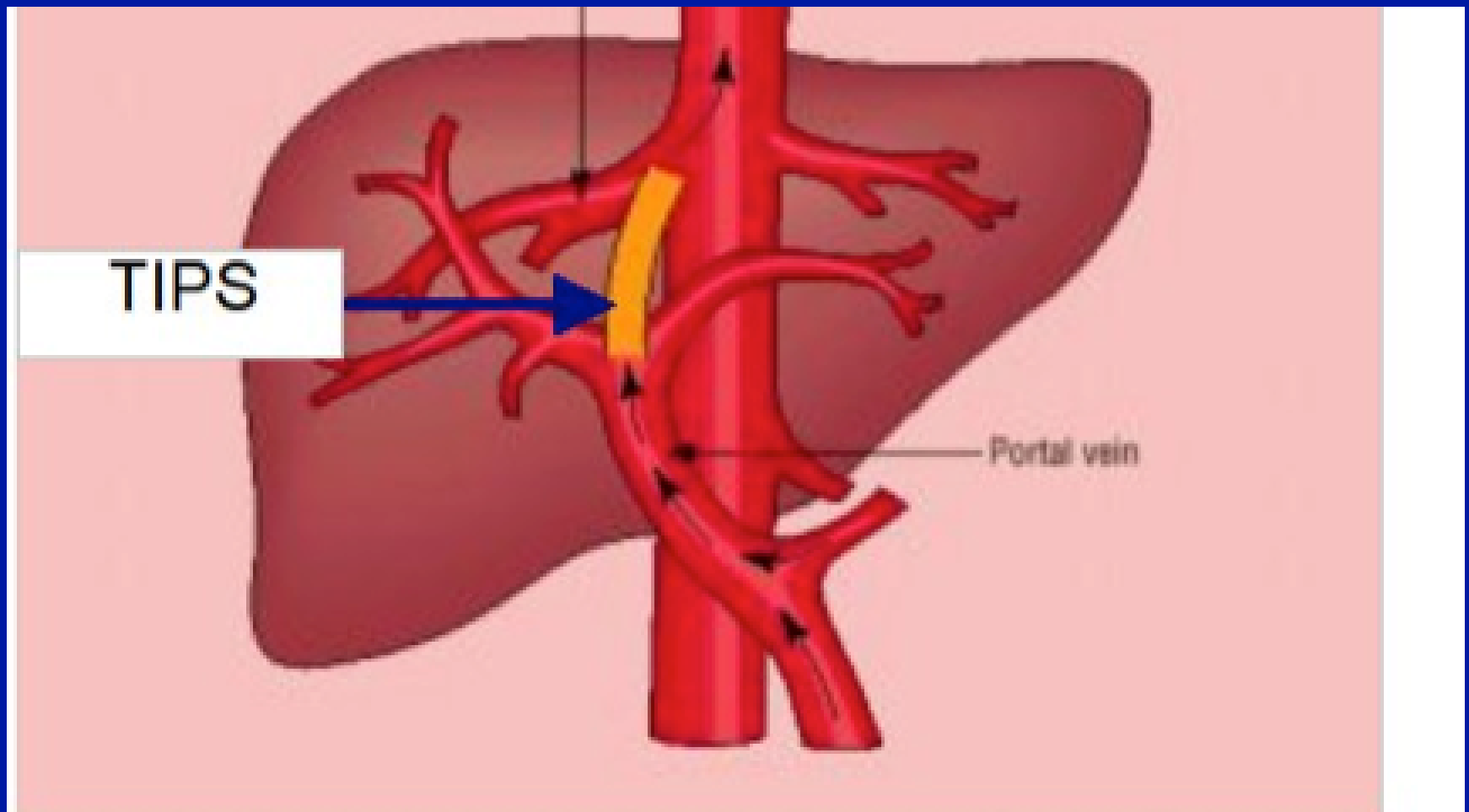


# Indications for Surgery or Therapeutic Mesenteric Angiography

- Upper GI bleed with failed hemorrhage control by EGD or re-bleed with failed control by repeat EGD
- Lower GI bleed with ongoing hypotension despite transfusion and octreotide
- Any source with hemodynamic instability despite vigorous resuscitation and 3 units PRBC's or continuous bleed 3 units/day

*Over 95% cases do not require surgery or angiography*

# TIPPS as Salvage if Endoscopy Fails to Control Variceal Hemorrhage



Mortality with Emergency TIPPS Less Than Operative Shunt Surgery



# Case One - Hematemesis

- 43 year old painter with sudden nausea and bright red blood **hematemesis** is brought by car to your emergency department. He admits to drinking a *six pack of beer daily*. He takes no medications.
- He looks pale, **SBP is 100, pulse is 105**, abdomen is soft with hyperactive bowel sounds. He has a few *spider angiomas* on his chest
- He asks for a bed pan and passes a large amount of **maroon stool**, then he passes out.

*How do you manage this case?*

# Hematemesis and Maroon Stool

## Big Vessel, Upper Source

### Management

- Intubate to protect airway, carefully sedate
- Two large bore IV's or central line
- Packed cell transfusion (2-4U), goal Hgb 8
- IV Octreotide 50mcg/hr
- IV continuous PPI
- IV Erythromycin 250mg over 30 minutes
- IV Ceftriaxone or Fluoroquinolone

**Emergency Endoscopy Now!**

# Case Two – Rectal Bleeding

- 68 yr old frail female brought by ambulance from the nursing home after falling while ambulating to the bathroom. Medicines include **aspirin**, **clopidogrel** (post stroke) and **ibuprofen** for arthritis. She reports **occasional dark stools, and occasional red stools**
- She is pale, mildly confused, and tachypneic , with SPB 105 heart rate 98 and irregular. Her abdominal exam reveals **tenderness in the left low quadrant** without rebound, a **rectal exam reveals dark brown solid stool with reddish secretions.**
- **Hemoglobin is 6.4 with MCV 70. Creatinine is 2.4**

# Iron Deficiency Anemia (low MCV)

## Small Vessels/Mucosal Lesions

### ■ Clinical Concern:

- She has **symptomatic anemia** (syncope, exertional fatigue)
- Be concerned about demand cardiac ischemia

### ■ Management:

- Admit to monitored bed, consult cardiology
- STOP ibuprofen, continue aspirin and clopidogrel
- **DELAY ENDOSCOPY UNTIL TRANSFUSED AND STABLE**

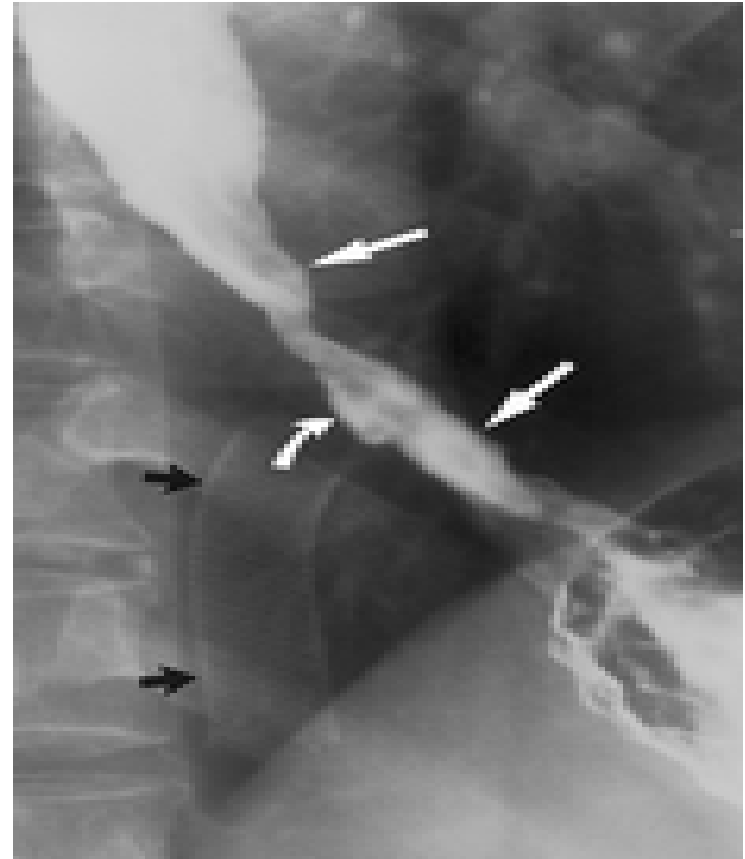


# Endoscopy for GI Bleeding Summary

- Early EGD is the best predictor for hospitalization, ICU admission, diagnosis, prognosis, and treatment
- Colonoscopy main use to diagnose lower GI bleeding cause, although newer techniques can be therapeutic
- Angiography, TIPSS or emergent surgery are needed <5% of time
- The optimal timing for emergent EGD has not been adequately determined; for massive bleeding earlier intervention should confer better outcome, in all others endoscopy within 24 hours is sufficient.

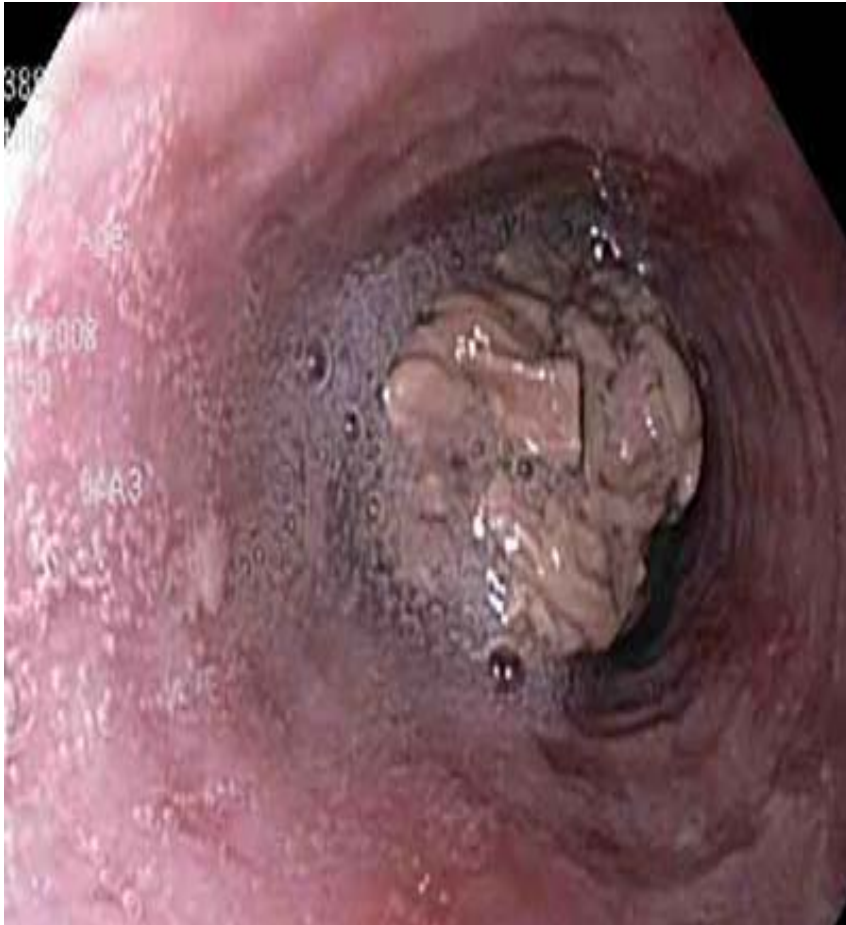# Emergency Endoscopy Applications

- Upper and Lower GI bleeding
- **Obstructed esophagus**
- Foreign Body Removal
- Caustic Ingestions



# Esophageal Obstruction

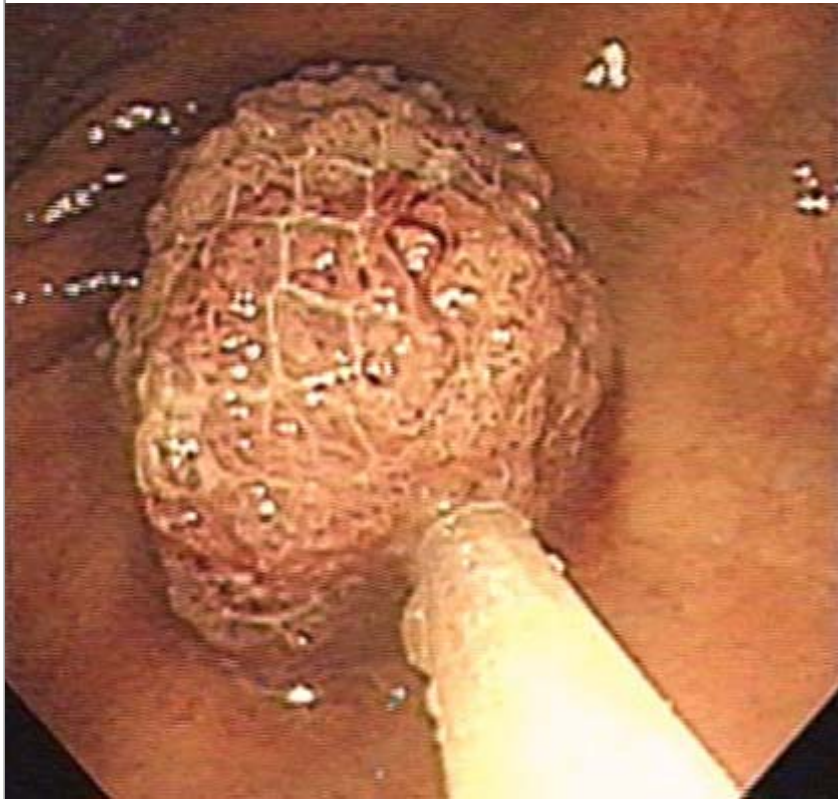
## Food Impaction Most Common



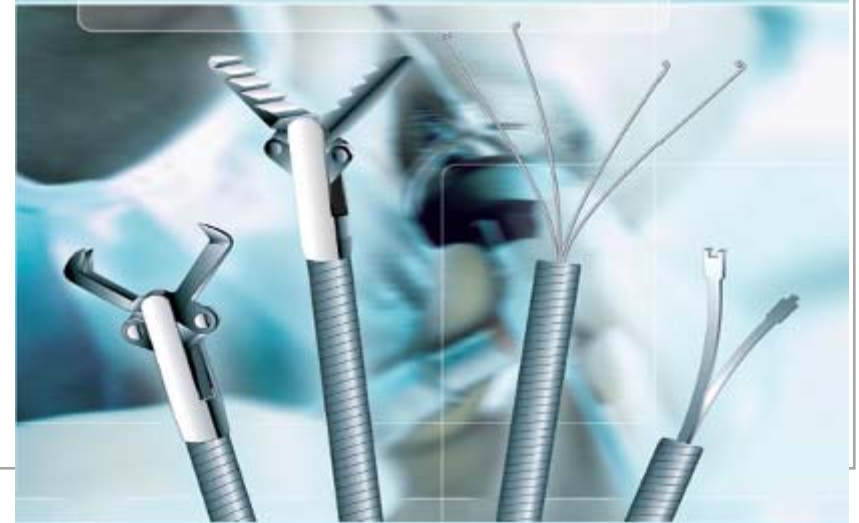- Do obtain lateral neck films if “stuck in throat”
- Try IV glucagon 0.5mg boluses, up to 2mg
- Early endoscopy is advised; fluoroscopy is helpful
- Please don't order barium esophagram



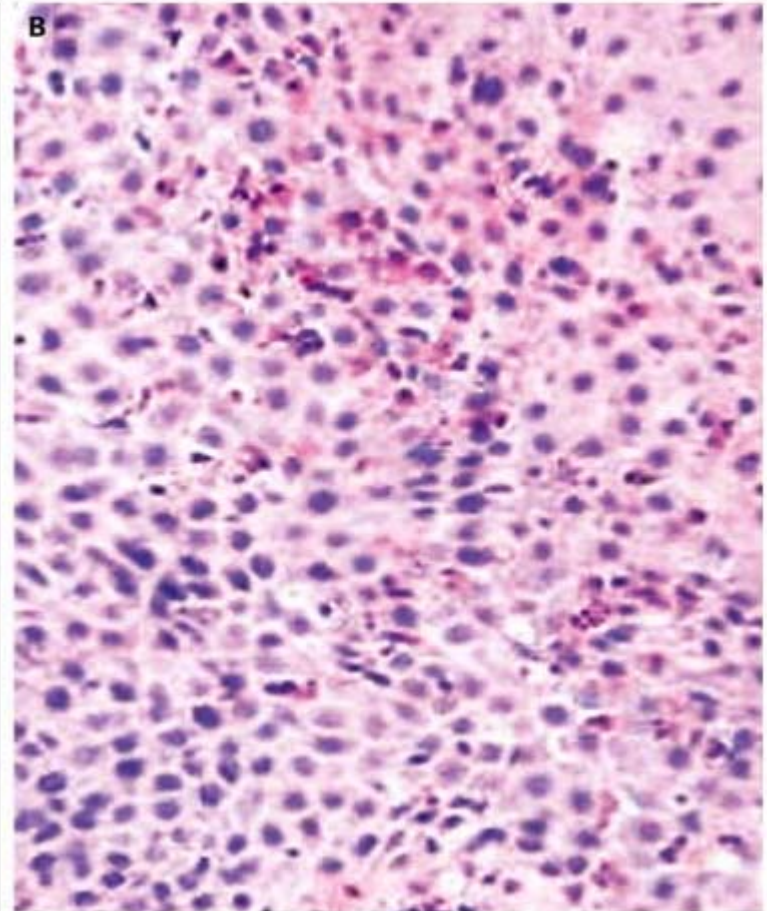
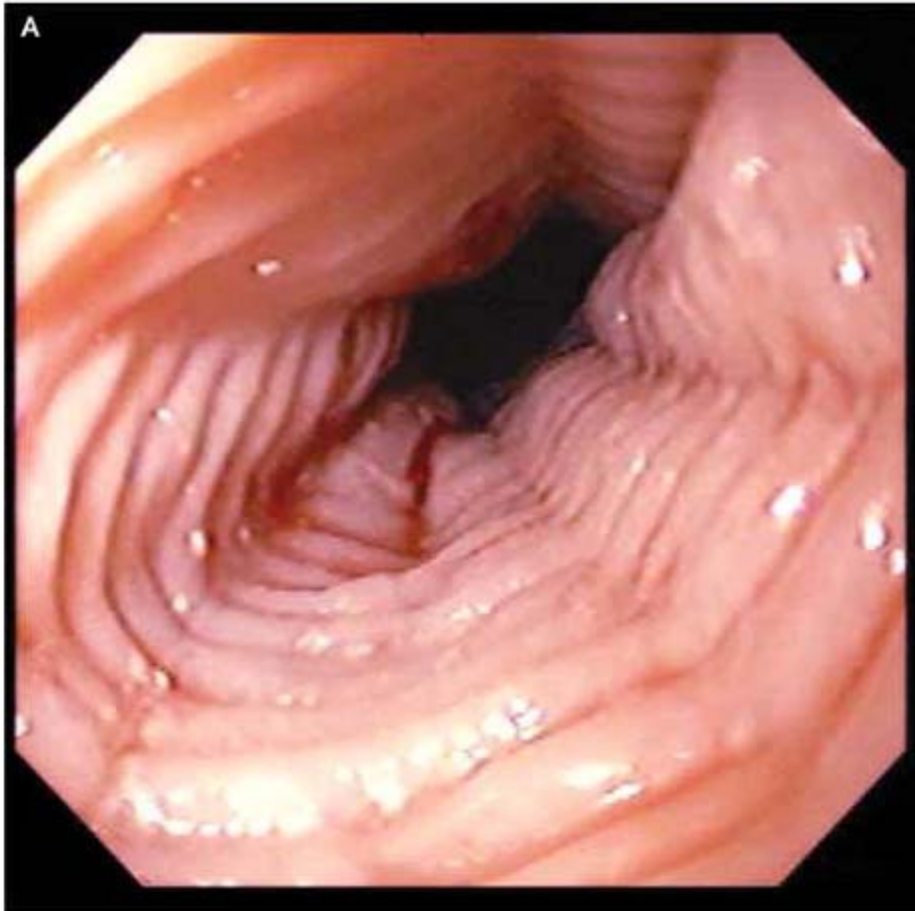
# Foreign Body removal



Foreign Body Retrievers  
Reusable

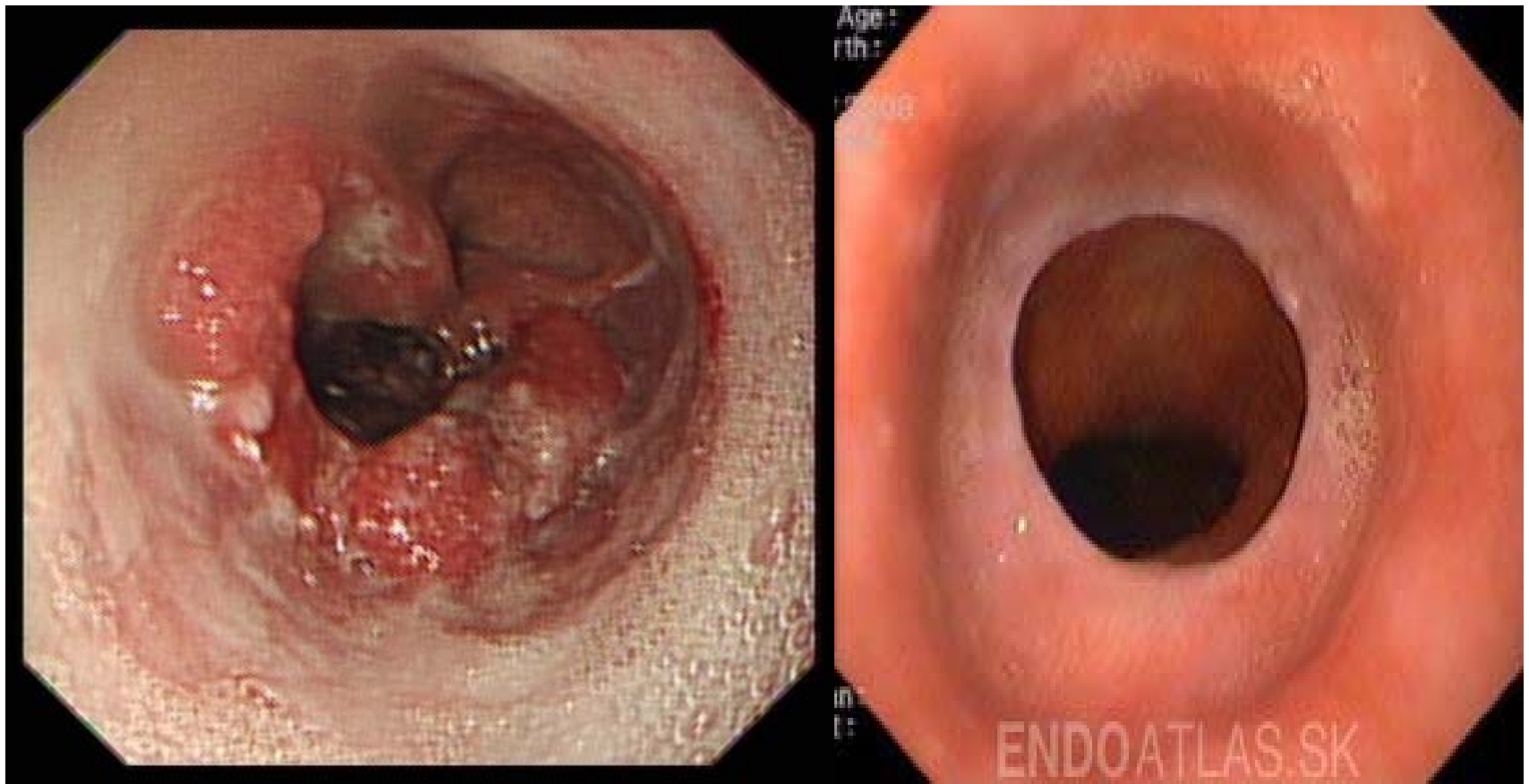


# Multiple Benign Strictures Eosinophilic Esophagitis





# Malignant vs. Benign Strictures



# Stents Restore Luminal Patency

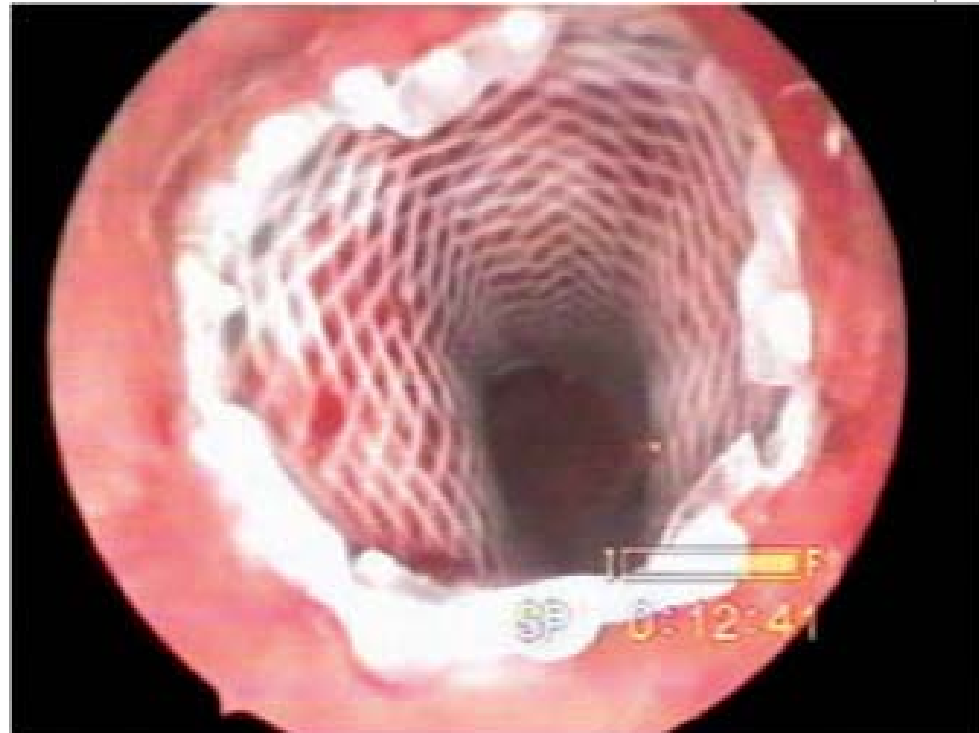
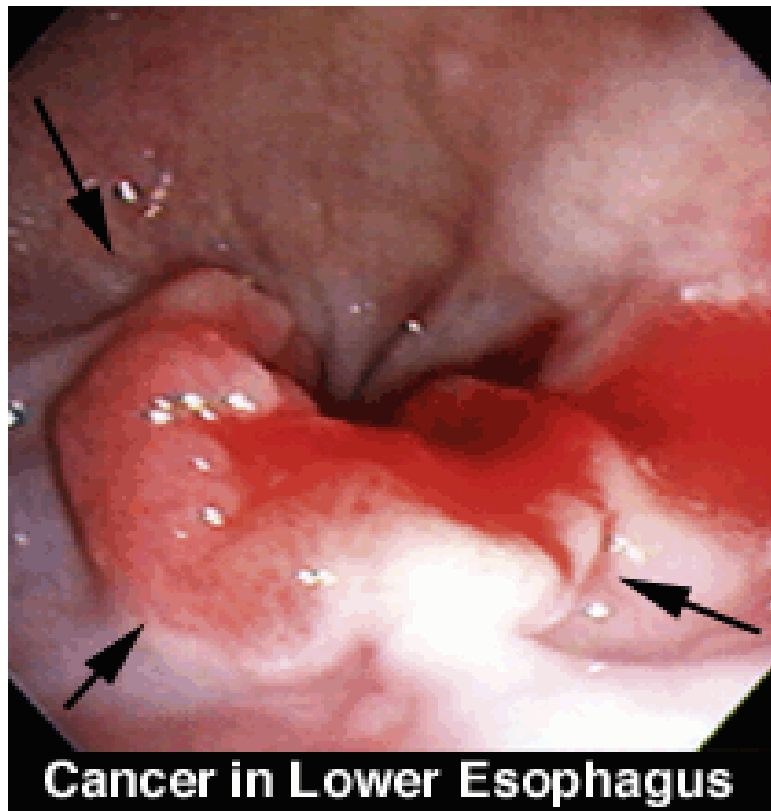
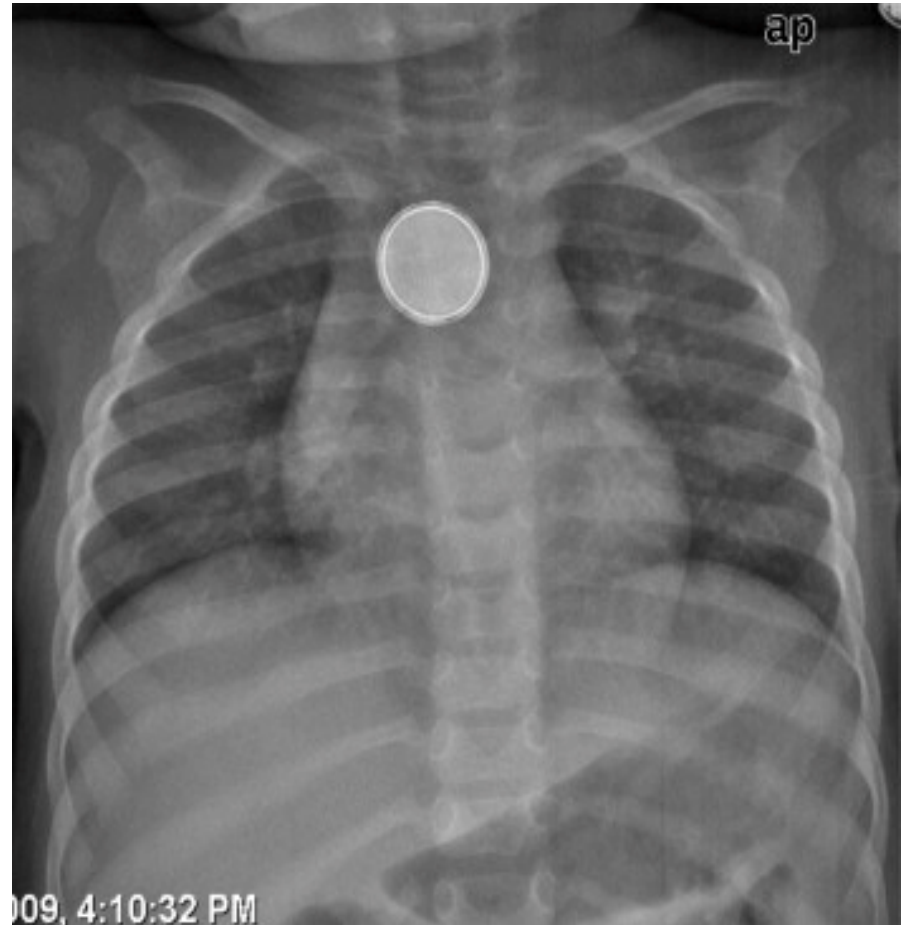

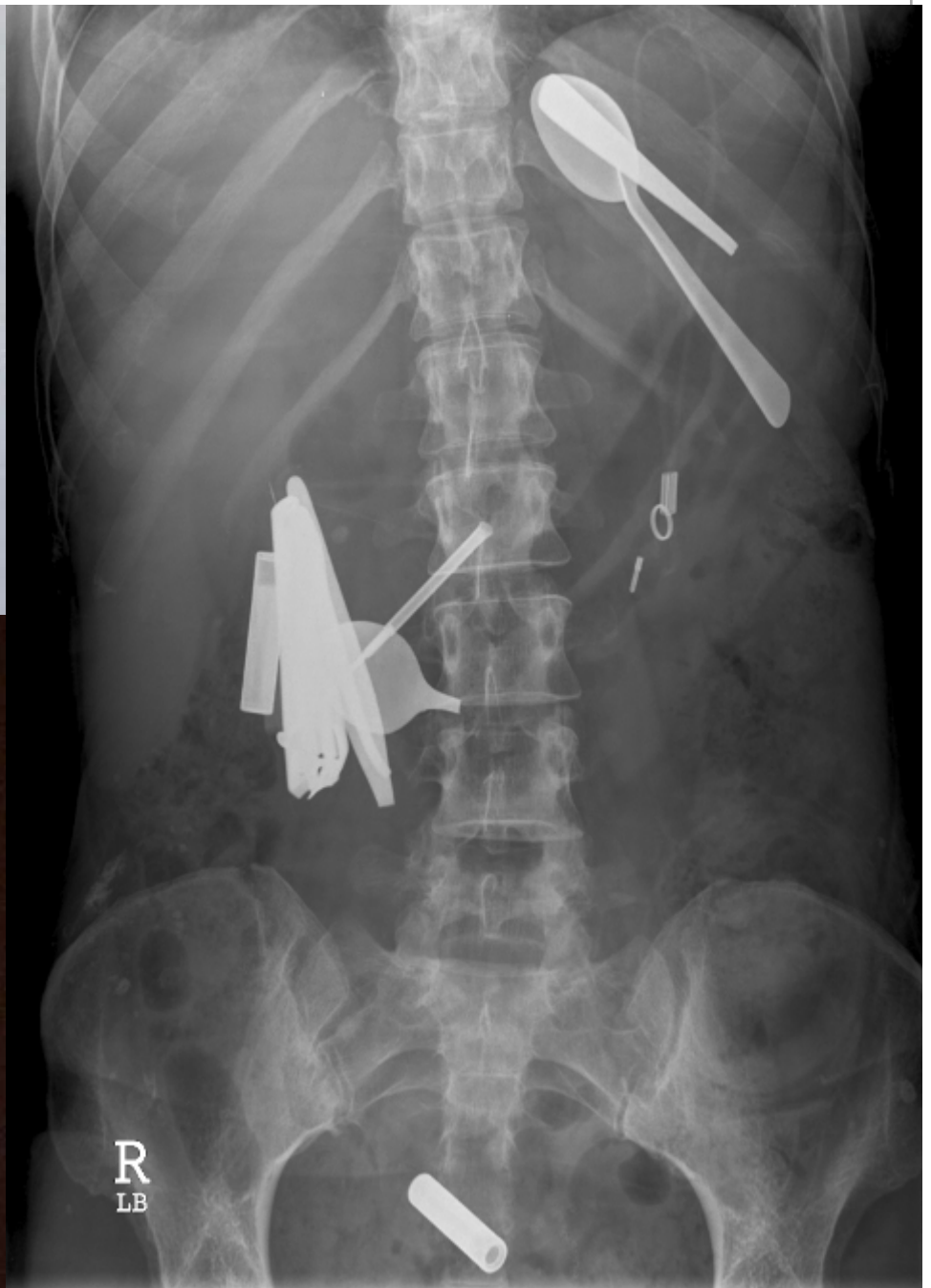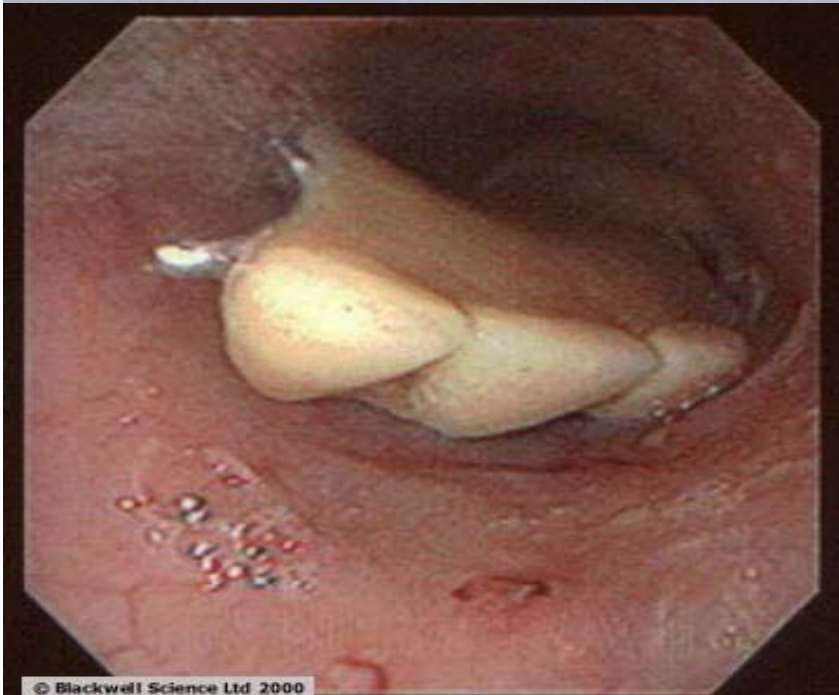Figure 2 - Polyflex® stent within the trachea.



# Emergency Endoscopy Applications

- Upper and Lower GI bleeding
- Obstructed esophagus
- **Foreign Body Removal**
- Caustic Ingestions





# Foreign Body Removal Considerations

## Benign Object

- Able to pass through GI tract
- No harm to the patient
- May observe however follow-up x-ray needed to ensure passage
- Metal objects: advise against MRI until cleared

## Sharp/Caustic Object

- Unable to pass through GI tract
- Can cause injury
- Emergent endoscopy/Surgery
- Consider General Anesthesia
- Use of overtube to retrieve sharps

# Emergency Endoscopy Applications

- Upper and Lower GI bleeding
- Obstructed esophagus
- Foreign Body Removal
- **Caustic Ingestions**





# Caustic Ingestions

## Emergency Management

### DO the Following

- Identify ingredients, concentration and volume consumed; call poison control
- Assess airway, start IV fluids
- Gentle oropharyngeal intubation with direct visualization
- NG suction if early, and for acid ingestions
- Chest, abdominal x-rays

### DO NOT:

- Give diluents
- Induce vomiting
- Give activated charcoal

# Involve Consultants Initially

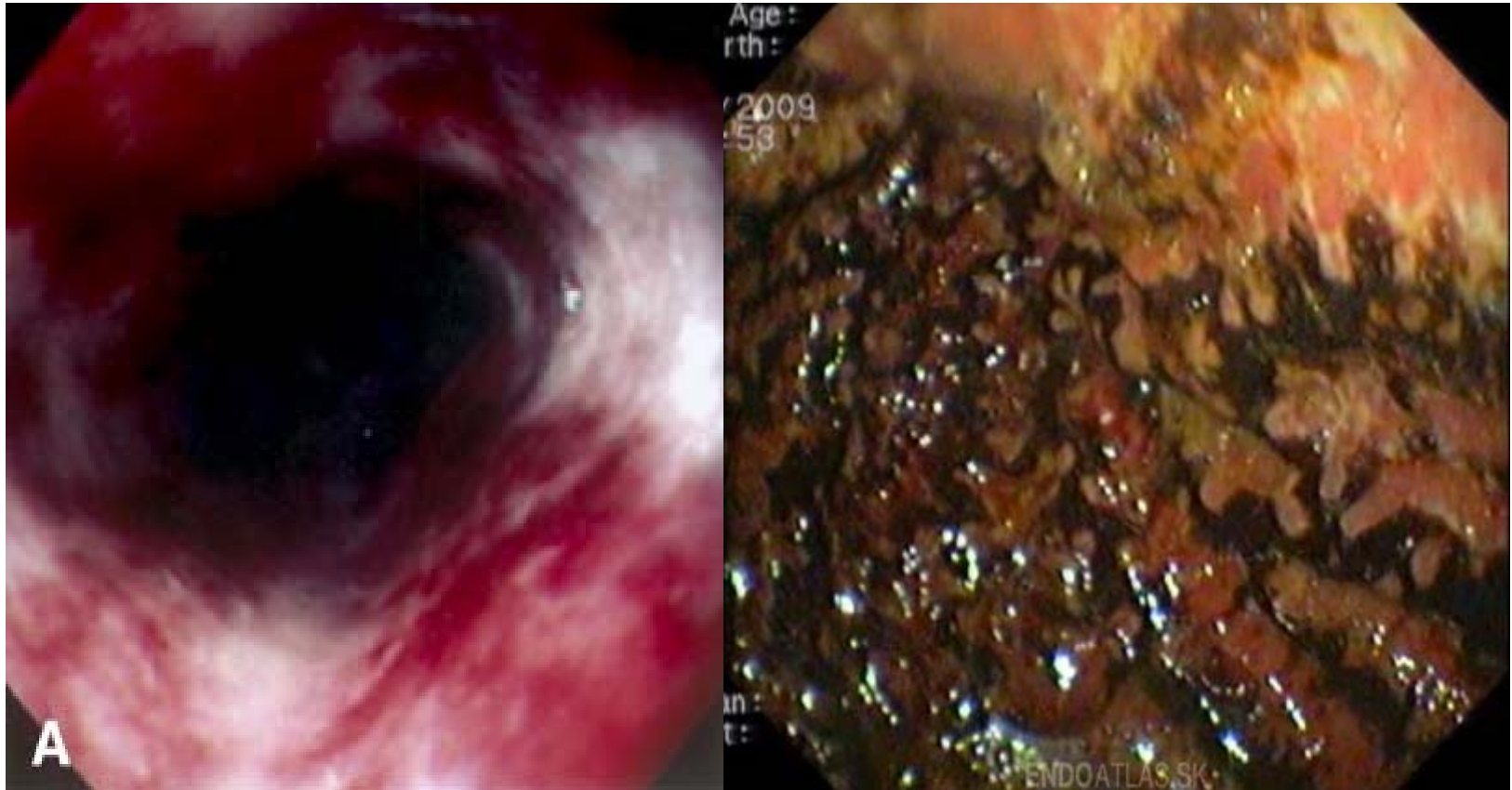
## Endoscopy

- Small children
- Symptomatic adults
- Altered mental status
- Intentional ingestions

## Surgery

- Perforation
- Mediastinitis
- Peritonitis

# Early Endoscopy Guides Management



# EMERGENCY ENDOSCOPY

## SUMMARY:

- Very effective for GI bleeding site control and to guide medical management
- Best option for diagnosis and treatment of esophageal obstruction
- May obviate the need for surgery in foreign body ingestion
- Aids in staging and management of caustic ingestions
- *We need multicenter randomized controlled trials to determine optimal timing of endoscopy for upper GI bleeding; with application to the type of bleeding lesion (large vs. small vessel)*