


# SCIENTIFIC AMERICAN™

Permanent Address: <http://www.scientificamerican.com/article.cfm?id=virtues-of-the-virtual-autopsy>



## Virtues of the Virtual Autopsy

Medical imaging offers new ways to examine the deceased

By Maryn McKenna | Monday, October 22, 2012

Once a common medical procedure, the standard autopsy is passing out of use. In the 1970s bodies underwent postmortem examination in nearly 20 percent of deaths in the U.S. By 2007 the rate had fallen to 8.5 percent of all deaths and to only 4.3 percent of deaths caused by disease.

The reasons for the decline are well documented. Autopsies reveal medical mistakes, making doctors and hospitals uncomfortable. Medicare and private insurance do not reimburse providers for the procedures, so families must pay in full. And in the increasingly diverse U.S., members of some religions, such as Orthodox Judaism or Islam, object to dissecting a body after death.

Yet autopsy is a time-honored and reliable tool for confirming, or questioning, the actions of both medicine and law enforcement, so pathologists have looked for a viable alternative. Inspired by rapid technological improvements, researchers in several countries have been exploring the possibility that medical imaging—in particular, MRI and CT scans—might substitute a “virtual autopsy” for the more traditional variety.

“The findings so far are mixed,” says Elizabeth Burton, a visiting associate professor of pathology at Johns Hopkins University. Virtual autopsy, she says, “is better for examining trauma, for wartime injuries, for structural defects. But when you start getting into tumors, infections and chronic conditions, it’s not as good, and I doubt it will ever be better.”

After about a decade of research, proponents concede that various difficulties—including high cost, competition for access to imaging machines and some inherent limitations of the technology—will likely prevent virtual autopsies from fully replacing the hands-on version. Nevertheless, the new techniques are answering cause-of-death questions that have frustrated traditional autopsies and are sidestepping religious objections. By enhancing medical education and suggesting improvements in emergency care, virtual postmortem examination is helping the living, too.

### Forensic Frontier

Postmortem imaging began as a laboratory technique in legal investigations. Dissection usually destroys tissues, but a research group in Bern, Switzerland, recognized that advances in imaging technology would let them look deep into tissues while preserving evidence. In the early 2000s they combined MRI and CT scanning with computer-aided 3-D reconstruction to prove causes of death for

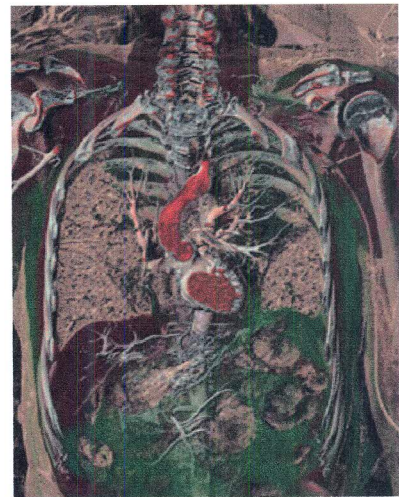

Image: COURTESY OF ANDERS PERSSON Center for Medical Image Science and Visualization


ADVERTISEMENT



This is My Kentucky



University of Kentucky



difficult cases, which included drownings, flaming car crashes, and severe injuries to the skull and face.

Their process, which they dubbed “virtopsy,” ignited interest in applying postmortem imaging to other forms of traumatic injury. Since 2004 the U.S. military has performed x-rays and CT scans on the bodies of every service member killed where the armed forces have exclusive jurisdiction—that is, not just on battlefields abroad but on U.S. bases as well. Imaging “is an adjunct to the traditional external and internal postmortem exam,” says Edward Mazuchowski, chief deputy medical examiner in the Armed Forces Medical Examiner System. “It allows us to identify any foreign bodies present, such as projectiles. X-rays give you the edge detail of radio-opaque or metallic objects, so you can sort out what the object might be, and CT, because it is three-dimensional, shows you where the object is in the body.”

Along with analyzing causes of death, the virtual exams help to assess the accuracy of medical care in the field. Through imaging, examiners can detect whether medical devices, such as breathing tubes and long needles that can decompress a collapsed lung, performed as expected or fell short. Those analyses spur improvements such as lengthening needles to make sure they penetrate soldiers' sturdy musculature, as well as redesigning body armor to protect against the shrapnel scattered in unpredictable patterns by improvised explosive devices.

Virtual autopsy has moved into civilian forensics as well. In Melbourne, Australia, postmortem CT scanning has been part of legal investigations of deaths since 2005. In the U.S., at least two state medical examiners' offices, in New Mexico and Maryland, routinely use it. The Maryland office, according to Chief Medical Examiner David Fowler, applies CT to roughly half its autopsies, which amounts to about 2,000 cases a year. Imaging has proved invaluable, he says, for “pediatric cases, motor vehicle collisions and drownings” and has revealed causes of death in cases where dissection would destroy evidence, such as air sucked into blood vessels during trauma or dialysis and sports injuries to the vertebral artery, which snakes through the bones of the neck.

In hospitals, the value seems more mixed. Two 2009 research reviews by teams in the U.K. and the Netherlands found that virtual autopsies differed widely in accuracy, depending on whether the deceased was an infant, child or adult and on whether the cause of death was trauma or an infectious or chronic disease.

This past January a study conducted among intensive care unit patients in Germany compared diagnoses made before death with the results of both traditional and virtual autopsy in 47 patients and with only virtual autopsy in another 115 whose families refused standard autopsy. Virtual autopsies confirmed 88 percent of diagnoses made before death, not far behind the 93 percent rate for traditional postmortem exams. Although virtual autopsies tended to miss fatal heart attacks and blood clots in the lung and major blood vessels, traditional autopsies were not perfect either: they missed important fractures, fluid around the heart and collapsed lungs.

Dominic Wichmann, a specialist in internal medicine at University Medical Center Hamburg-Eppendorf in Germany and the study's first author, says the large number of instances where postmortem exams were refused underlines a situation in which virtual autopsy is essential: cases where cause of death is uncertain, but a standard autopsy violates religious rules.

Although no one keeps comparative records, the U.S. institution with the most virtual-autopsy experience may be Massachusetts General Hospital, which has conducted more than 125 procedures since 2010 under the direction of Mannudeep Kalra. He says that virtual autopsies help to establish frank causes of death such as air embolisms. Its biggest apparent shortcoming—failure to identify cardiovascular disease—is easily explained, he says: there is no circulation to move around the contrast medium that illuminates blood vessels from the inside. To solve this problem, several research teams are contemplating using heart-lung machines or similar pumps.

### **On the Table**

Mass general, a teaching hospital of Harvard Medical School, is one of various academic medical centers to invest in the latest iteration of postmortem imaging technology: a virtual-autopsy table—essentially a giant iPad—that transforms the data from the scans into a 3-D animated image that doctors can “dissect” layer by layer with hand gestures. The Case Western Reserve University School of Medicine uses a virtual-autopsy table built by Swedish firm Sectra AB, while Harvard, Stanford University, the University of Texas at Austin and the University of Wisconsin–Madison have bought tables built by Silicon Valley–based Anatomage.

The biggest barrier to wider adoption of virtual autopsy is the cost of equipment and personnel. Virtual-autopsy tables are expensive; Anatomage's costs \$60,000. The scanners used for MRI and CT cost hundreds of thousands of dollars, but most medical centers already have them. The true challenge is finding ways to pay technicians because autopsies—real or virtual—are not reimbursed procedures.

"I think compensation is going to be the rate-limiting step," says Gregory Davis, a pathology professor at the University of Kentucky College of Medicine. Hospital radiology departments, he points out, already have hectic schedules full of appointments with paying patients. Establishing a virtual-autopsy program often requires staff and faculty to work outside standard hours and obtain scarce grants or donate their time.

Given these issues of cost, radiologists will probably not replace pathologists as final arbiters of cause of death. Still, many pathologists think virtual autopsy is a crucial adjunct to traditional autopsy. And the resulting images, whether rendered on an Anatomage or presented on a laptop, could provide medical students with something they sorely need: an opportunity to participate in a vanishing practice. Anatomage markets its table as a teaching tool that allows students to practice surgery and lengthy dissection techniques, which heretofore required dead bodies.

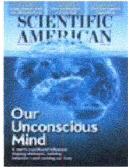
"So few autopsies are being done now that many medical students get out of school never having seen one," Davis says. "And yet in medicine, autopsy is the most powerful quality-control technique that we have and the reason we know as much as we do about many diseases and injuries. Using imaging could bring back a familiarity with autopsy, and that is definitely worthwhile."

#### SCIENTIFIC AMERICAN ONLINE

Comment on this article at [ScientificAmerican.com/nov2012](http://ScientificAmerican.com/nov2012)

**TRY A RISK-FREE ISSUE**

**YES!** Send me a free issue of Scientific American with no obligation to continue the subscription. If I like it, I will be billed for the one-year subscription.



Email Address

Name