

Lentigo Maligna: Striking a Balance With the Risk-Benefit Ratio

Glen M. Bowen, MD

Huntsman Cancer Institute

University of Utah

I. Objectives:

- a. Review the terminology of LM/LMM
- b. Understand the relative risk of death from a locally recurrent LM
- c. Be familiar with treatment options for LM
- d. Review biopsy techniques for suspected LM
- e. Understand the histologic features of LM and the ambiguity inherent in distinguishing between positive and negative surgical margins
- f. Review techniques for decreasing surgical morbidity

II. Disclosures:

I will discuss the off-label use of topical imiquimod 5% cream in the neo-adjuvant setting prior to the staged excision of lentigo maligna.

I have no financial disclosures.

III. Analysis of Risk:

- a. Huntsman Cancer Institute Data on 2104 patients with LM/LMM (16 years)
- b. 1.8% recurrence rate of LM at ≥ 5 years follow-up (522 cases)
- c. 20% of local LM recurrences are invasive (average Breslow depth = 0.35 mm)
*all cases were Stage IA
- d. 5-year survival for Stage IA = 95%
- e. Risk of death at 5 years from a local recurrence of LM is:
 - i. 1.8% recur, 20% of which are invasive, 5% of which would be expected to die at 5 years
 - ii. Risk of death at 5-years = 0.018%
- f. Given the very low risk of death from a locally recurrent LM, it seems that the morbidity of the treatment should be balanced by the relative risk to the patient

IV. Histologic Definition of LM:

- a. Ackerman defined 12 histologic criteria for making a distinction between LM and surrounding atypical junctional melanocytic hyperplasia common to chronically sun-exposed skin (*Ackerman AB, Briggs PL, Bravo F. Differential diagnosis in dermatopathology. III. Philadelphia: Lea & Febiger, 1993:166-9*)

- b. Key criteria:
- i. Pagetoid spread
 - ii. Vertical stacking
 - iii. Theque formation
 - iv. Confluence along the dermoepidermal junction
 - v. Adnexal extension
- c. “Negative controls” are biopsies sampled at the time of staged excisions for LM usually taken from a contralateral site not involved with LM. In reviewing our negative controls, we found the following frequencies of Ackerman’s histologic criteria:
- i. Pagetoid spread: 33%
 - ii. Vertical stacking: 49%
 - iii. Theque formation: 13%
 - iv. Confluence along the dermoepidermal junction: 39%
 - v. Adnexal extension: 87%
 - vi. Conclusion: Key histologic features of LM can often be found in chronically sun-damaged skin. Making a distinction between LM and atypical junctional melanocytic hyperplasia is not as straight forward as found in the literature.
Immunohistochemical staining with Melan-A of uninvolved sun-damaged skin shows features characteristic of lentigo maligna. *Bowen AR, Perry Thacker BN, Goldgar DE, Bowen GM. Dermatol Surg. 2011;37(5):657-63.*
 - vii. *The one histologic criteria that was statistically significant in making a distinction between LM and AJMH was **melanocyte density**:*

<u>AJMH</u>	<u>LM</u>
26 +/- 9 cells/400x	83 +/- 29 cells/400x
 - viii. This conclusion was recapitulated from a group in the UK, i.e. only melanocyte density was significant in predicting local recurrences of LM.

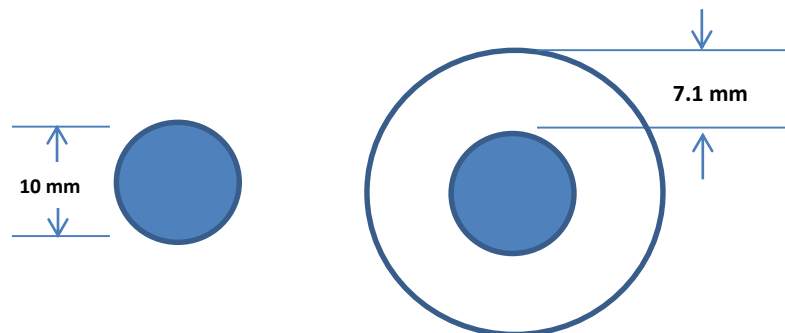
A model for lentigo maligna recurrence using melanocyte count as a predictive marker based upon logistic regression analysis of a blinded retrospective review.
Gorman M, et al. J Plast Reconstr Aesthet Surg. 2014;67(10):1322-1332
- d. How “gold” is the “Gold Standard” for the histologic diagnosis of LM?
- i. 27 cases of LM treated with staged excisions with permanent sections were reviewed by 5 dermatopathologists. *Florell SR, et al. Arch Dermatol. 2003 May;139(5):595-604.*

- ii. 72% concordance with the original diagnosis of LM
- iii. Inter-observer agreement: κ range, 0.4-0.5 = moderate
- iv. Intra-observer agreement: κ range, 0.6-0.9 = moderate to good
 - This connotes that the pathologist read it as “positive” on the first read but “negative” on the second blinded read or vice versa
- v. The use of a “negative control” improved concordance rates on difficult cases from 46% to 76% ($p = 0.001$)

V. Decreasing Surgical Morbidity: the following are the steps we currently use for LM of the face at the Huntsman Cancer Institute:

The average margin required to confirm negative margins in LM is 7.1 mm.

Hazan C, Dusza SW, Delgado R, Busam KJ, Halpern AC, Nehal KS. *J Am Acad Dermatol.* 2008;58(1):142-8.



Assuming an LM with a 10 mm diameter,
the surgical defect will have a diameter of 24.2 mm

Here are the steps we follow to try to reduce the size of the surgical defect:

- a. Remove all of the visible tumor with an excisional biopsy with no margins and repair with a purse string
- b. Rationale:
 - i. 16% of LM referred to us for treatment is invasive. This needs to be ruled out and the tumor properly staged before embarking on neo-adjuvant topical therapy.

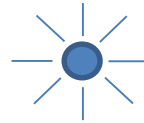

Two separate studies from the Huntsman Cancer Institute and later from Sloan-Kettering showed the same number: 16% of LM are invasive and upstaged to LMM.

Agarwal-Antal N, Bowen GM, Gerwels JW. *J Am Acad Dermatol.* 2002;47(5):743-8.

Hazan C, Dusza SW, Delgado R, Busam KJ, Halpern AC, Nehal KS.

J Am Acad Dermatol. 2008;58(1):142-8.

- ii. Removing the visible LM and then closing the defect with a purse string maximally decreases the surface area of the tumor footprint. We allow the biopsy site to heal for 1-2 months before starting topical imiquimod.



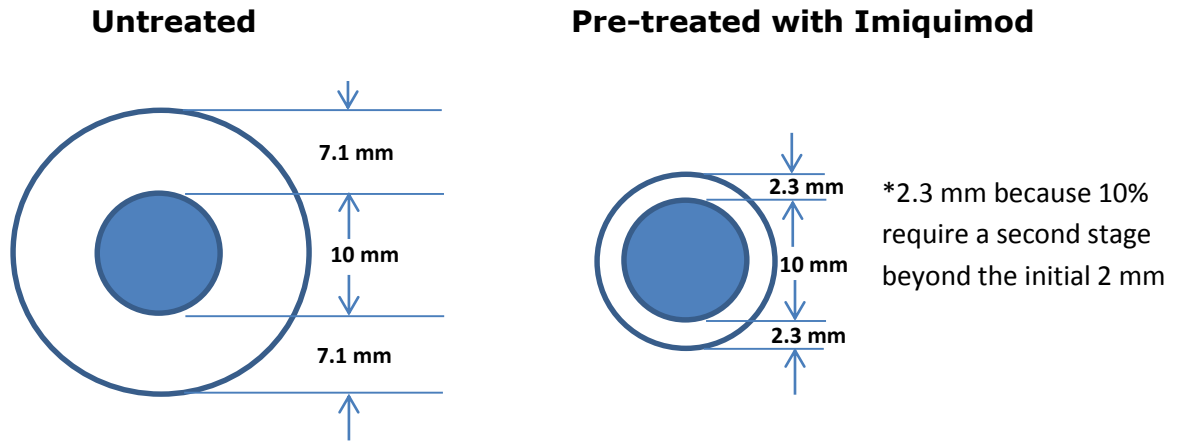
** The unsightly crenulations/folds of the purse string will have mostly flattened out after 1-2 months*

Original tumor footprint

Tumor footprint after purse string

- iii. We trace a template of the tumor outline with a Sharpie on clear plastic. After that, we put a small India ink tattoo in the center of the LM site so we can accurately center the template at the time of surgery.
- iv. The patient applies topical imiquimod 5% cream Monday-Friday for two months. We see them after the first and second month to record the degree of inflammation and make a dosage adjustment if necessary.
 - We grade the inflammation as follows:
 - 0= no sign of inflammation
 - 1 = pink
 - 2 = red
 - 3 = red with erosion, oozing, or eschar formation
- v. We discontinue the topical imiquimod after 2 months and then let the area cool off for 2-6 months for two reasons:
 - Surgery right at the time of cessation of topical imiquimod is difficult due to the high degree of inflammation obscuring the histological interpretation of margins
 - Some believe that there are ongoing therapeutic latent effects after the imiquimod is discontinued as is seen after radiotherapy for LM
- vi. A conservative staged excision is performed with 2 mm margins
 - We use radial sections since they allow one to see the tumor fade out in intensity from the center to the perimeter edge
 - We use H & E as well as immunostaining with Mart-1 (sensitive) and SOX-10 (specific)
 - We put in traction sutures to close the wound which allows the skin to stretch out during the 2 hours of processing time

- Most defects are closed primarily



Area of a circle = πr^2

VI. $\pi \times (12.1)^2 = 460 \text{ mm}^2$

$\pi \times (7.3)^2 = 167 \text{ mm}^2$
gists,

The surgical defect size can be reduced by 64%!

invasion is 0.018% at 5 years. For this reason, we feel that the morbidity of the surgical approach to LM should be minimized as much as possible.

- c. There are many treatment options available for LM such as:
 - i. Staged excisions with permanent *en face* or *radial sections*
 - ii. Staged excisions with frozen sections and immunostaining with Mart-1 +/- SOX10 with Mohs sections or radial sections (we prefer radial sections)
 - iii. Topical imiquimod: we do not use it as monotherapy since 30% of patients are found to have residual LM after topical treatment. For this reason, we use it in the neo-adjuvant setting.
 - iv. Radiotherapy: most of our patients refuse RT because it requires multiple fractions over 4-6 weeks and the cosmetic results deteriorate over time.
- d. Biopsy techniques:

We prefer **excisional biopsies** closed with a **purse string** repair to: 1) rule out invasion which is seen in 16% of LM cases, and 2) to decrease the surface area of the tumor footprint to its minimal size.
- e. Histology issues:
 - i. The “Gold Standard” of diagnosing LM with permanent sections is problematic with only 72% of pathologists agreeing on the initial

diagnosis and only moderate agreement between pathologists on what constitutes a “negative” and a “positive” margin.

- ii. The submission of a **negative control** statistically improves the concordance rate between pathologists in difficult to read cases.
 - iii. We do not accept various claims defining the difference between LM and AJMH because the histologic criteria for making that distinction are not statistically significant.
 - iv. The most reproducible criterion in making a distinction is the **relative melanocyte density** between the excised LM and the patient’s negative control.
- f. Decreasing surgical morbidity:
- i. We believe that using **neo-adjuvant topical imiquimod** for 2 months prior to a conservative staged excision has the following benefits:
 - ii. It allows for a **reduction of the size of the surgical defect** by 64%.
 - iii. The local recurrence rate of LM pre-treated with topical imiquimod followed by a conservative staged excision with 2 mm margins is 1.8%.
 - iv. This does not put the patient at higher risk and does not subject them to the larger staged excisions that require an average of 7.1 mm in order to confirm negative histologic margins.

g. Final word:

We are not satisfied that the use of neo-adjuvant topical imiquimod 5% cream followed by conservative staged excisions is the ideal treatment for LM since 30% of treated patients will have residual LM on excision. We are actively looking into other options with the hope that we can improve the complete response rates over the 70% complete response rates seen with imiquimod.