

# Osteomyoplastic Transtibial Amputation: The Ertl Technique

Benjamin C. Taylor, MD  
Attila Poka, MD

## Abstract

Amputation may be required for management of lower extremity trauma and medical conditions, such as neoplasm, infection, and vascular compromise. The Ertl technique, an osteomyoplastic procedure for transtibial amputation, can be used to create a highly functional residual limb. Creation of a tibiofibular bone bridge provides a stable, broad tibiofibular articulation that may be capable of some distal weight bearing. Several different modified techniques and fibular bridge fixation methods have been used; however, no current evidence exists regarding comparison of the different techniques. Additional research is needed to elucidate the optimal patient population, technique, and postoperative protocol for the Ertl osteomyoplastic transtibial amputation technique.

Despite considerable advances in limb salvage and revascularization techniques, amputation is still performed because the creation of a pain-free, functional residual extremity may not be possible owing to the clinical scenario or the salvage technique used.<sup>1</sup> Advances in patient care and prosthetic design have increased patient function after amputation, and a large number of patients can return to many, if not all, of their preinjury activities.<sup>2</sup> The impact of a lower-extremity amputation on patients should not be minimized, however. These patients will have continued dysfunction throughout their lifetime.<sup>3</sup> Although somewhat controversial, the Ertl technique for osteomyoplastic amputation has been proposed as a reconstructive method that can further improve the outcomes of transtibial amputation.

Much of the current evidence regarding the Ertl technique is conflicting, and the indications for this procedure remain somewhat debated. Many different variations of the technique have been described, including

the use of a vascularized fibular strut, the presence or lack of an osteoperiosteal sleeve, and the use of various fixation constructs and postoperative regimens; these variations are major confounding influences on patient outcomes and warrant further investigation.

## History and Development

As early as 1920, Janos Ertl<sup>4</sup> recognized that patients with transtibial amputations were having substantial functional difficulties and were using the amputated stump as a passive attachment for a prosthetic. Ertl<sup>4</sup> believed that traditional transtibial amputation provided a nonphysiologic environment that was worsened by the often discordant motions of the tibia and fibula after loss of the distal articulations. In the initial description of the Ertl technique, the osteoplasty was performed with elevation of an osteoperiosteal sleeve from the distal tibia and fibula that was sutured at the end of these two bones to seal the

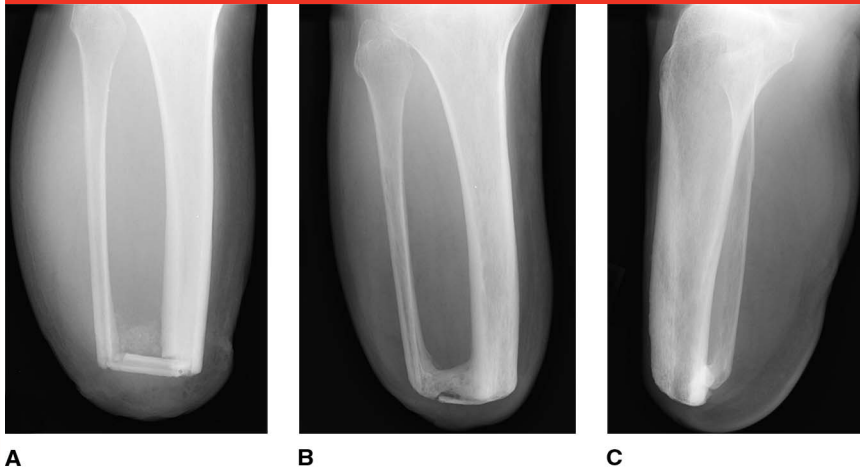
From the Department of Orthopaedic Surgery, Grant Medical Center, Columbus, OH.

Dr. Taylor or an immediate family member has received royalties from Zimmer Biomet; is a member of a speakers' bureau or has made paid presentations on behalf of Zimmer Biomet and Depuy Synthes; and serves as a paid consultant to Zimmer Biomet. Dr. Poka or an immediate family member is a member of a speakers' bureau or has made paid presentations on behalf of Stryker and serves as a paid consultant to Zimmer Biomet.

*J Am Acad Orthop Surg* 2016;24: 259-265

<http://dx.doi.org/10.5435/JAAOS-D-15-00026>

Copyright 2016 by the American Academy of Orthopaedic Surgeons.

**Figure 1**

**A**, AP radiograph of the lower extremity obtained immediately postoperatively demonstrating an osteomyoplastic transtibial amputation. Note the placement of an autogenous fibular strut across the distal aspect of the amputated tibia and fibula. **AP (B)** and lateral (**C**) radiographs of the extremity obtained 36 months postoperatively.

medullary canal and form a solid bony synostosis at the distal amputation stump.<sup>4</sup>

The bone bridging (ie, osteoplastic) component remains the most recognizable aspect of the Ertl technique, but descriptions of the procedure focus equally on the evaluation and treatment of the soft tissues. Individual ligation of each component of the neurovascular bundles is required to recreate a residual limb that is as physiologically similar to the native limb as possible, with transection of all nerves done while under tension to allow for proximal retraction. A meticulous myoplasty also is essential to create a well-balanced, stable limb with minimal muscle-related complaints; in fact, the myoplastic component of the procedure may be just as important as the bony aspects. The myoplasty or myodesis recreates the tension of muscles of normal length, increases and stabilizes the surface area available for prosthetic fitting, normalizes muscle function as viewed on electromyographic testing, and improves both the arterial and venous circulation of the residual stump.<sup>5-9</sup> Careful

attention to appropriate, tension-free skin closure is crucial to minimize wound healing complications.

Later investigation on the effect of sealing the medullary canal revealed that this closure led to a prompt recovery of the intramedullary pressure of the tibia, which was shown in several angiographic evaluations to improve medullary blood flow such that it was comparable to that of uninjured limbs.<sup>10</sup> In addition, this closure has been shown to increase blood flow to the residual limb, which may have important implications in healing.<sup>7,10</sup>

The Ertl technique has continued to evolve, with the most notable alteration of the original procedure described by Pinto and Harris.<sup>8</sup> They reported on a series of patients who underwent the procedure with the addition of an autogenous fibular strut placed across the distal aspect of the remaining tibia and fibula (Figure 1). Pinto and Harris<sup>8</sup> used heavy, nonabsorbable suture for fixation of the synostosis, but several different fixation methods have since been described, including small fragment screws, headless compression screws, and the TightRope

(Arthrex).<sup>11-13</sup> To date, no clinical studies have compared the use of various fixation constructs for the synostosis in transtibial amputation.

### Indications and Contraindications

The osteoplastic component of the Ertl technique adds surgical time to the procedure; however, we consider this component to be indicated for active patients who are able to regain mobility postoperatively. Patients who have had a traditional transtibial amputation may also benefit from a revision surgery with the Ertl technique to treat symptomatic instability of the residual tibia and fibula, also known as “chopsticking.”

Contraindications for the procedure include inadequate distal margins from an infection or neoplasm because harvest of the fibula and/or periosteal sleeve requires a longer healthy limb than that typically required for a traditional transtibial amputation. In early reports, the procedure was contraindicated in patients with diabetes mellitus or vascular insufficiency; however, larger case series that included these patients revealed that they can undergo the procedure successfully but may not achieve the same level of function as do patients without these comorbidities.<sup>9,12,14</sup>

### Authors' Preferred Technique

#### Preoperative Evaluation

Multimodal evaluation and treatment is often critical for patients who are candidates for the Ertl technique, and the involvement of a psychologist, physical therapist, social worker, prosthetist, vascular surgeon, and family physician may be necessary. Preoperative workup may also include laboratory or vascular perfusion studies; wound healing potential can be

predicted with an ankle-brachial index  $>0.5$ , transcutaneous oxygen levels  $>20$  mm Hg, a serum albumin level  $>2.5$  g/dL, and an absolute lymphocyte count  $>1,500/\mu\text{L}$ .<sup>15</sup> Finally, the surgeon should have an honest and candid discussion with the patient and his or her family regarding the procedure, its inherent limitations, and the inability to eliminate all pain; the value of fostering realistic patient expectations regarding such a procedure has been well documented.<sup>16</sup>

As with any surgery, a successful outcome is built on the foundation of a carefully constructed preoperative plan. High-quality biplanar radiographs of the knee, tibia, and ankle should be obtained, and additional advanced imaging studies (eg, MRI, CT, white blood cell-tagged studies) should be reviewed in developing the surgical plan. The surgeon should have information on any retained orthopaedic implants should intraoperative removal become necessary. Previous incisions, scars, and muscular flaps must be examined to ensure that the tissue is adequate for use. At the end of the procedure, a minimum of 10 to 15 cm of residual tibial length is necessary for an optimal prosthetic fit; if this length is not available, other surgical options may be necessary. Conversely, excessive residual tibial length can lead to delayed stump breakdown from decreased muscle and soft-tissue mass in the distal third of the leg. In general, the distance between the end of the stump and the ground should be at least 17 cm for most integrated foot and pylon shock-absorbing systems.

## Surgical Procedure

The patient is positioned supine, with a small bump placed under the ipsilateral hip to help control the limb's tendency to rotate externally. A radiolucent bed can be used when fluoroscopy is to be used for the osteoplastic portion of the

procedure. We recommend the use of general anesthesia and a well-padded tourniquet on the ipsilateral thigh.

A long posterior flap is created unless previous scars, wounds, or other factors require an alteration of the flap design. In these cases, vascular-based skew flaps, fish mouth flaps, long medial flaps, or sagittal flaps may be used. To create a long posterior flap, the anterior incision is drawn at the level of the intended tibial resection, with the posterior incision drawn approximately 1 cm distal than the diameter of the leg at the level of the tibial cut<sup>17</sup> (Figure 2). The apex of the incision is  $<90^\circ$  to minimize creation of protruding skin, or "dog ears." The anterior incision is carried through the anterior fascia, and the musculature of the anterior compartment is sharply transected inline with the incision. The anterior neurovascular bundle is then separated and ligated; we minimize formation of symptomatic neuroma by ligating each nerve as proximal as possible to decrease vascularity of the end of the transected nerve and by sharply cutting the nerve while it is under tension to allow it to retract proximally. After division of the anterior compartment is complete, the saphenous nerve is identified and treated in the same fashion.

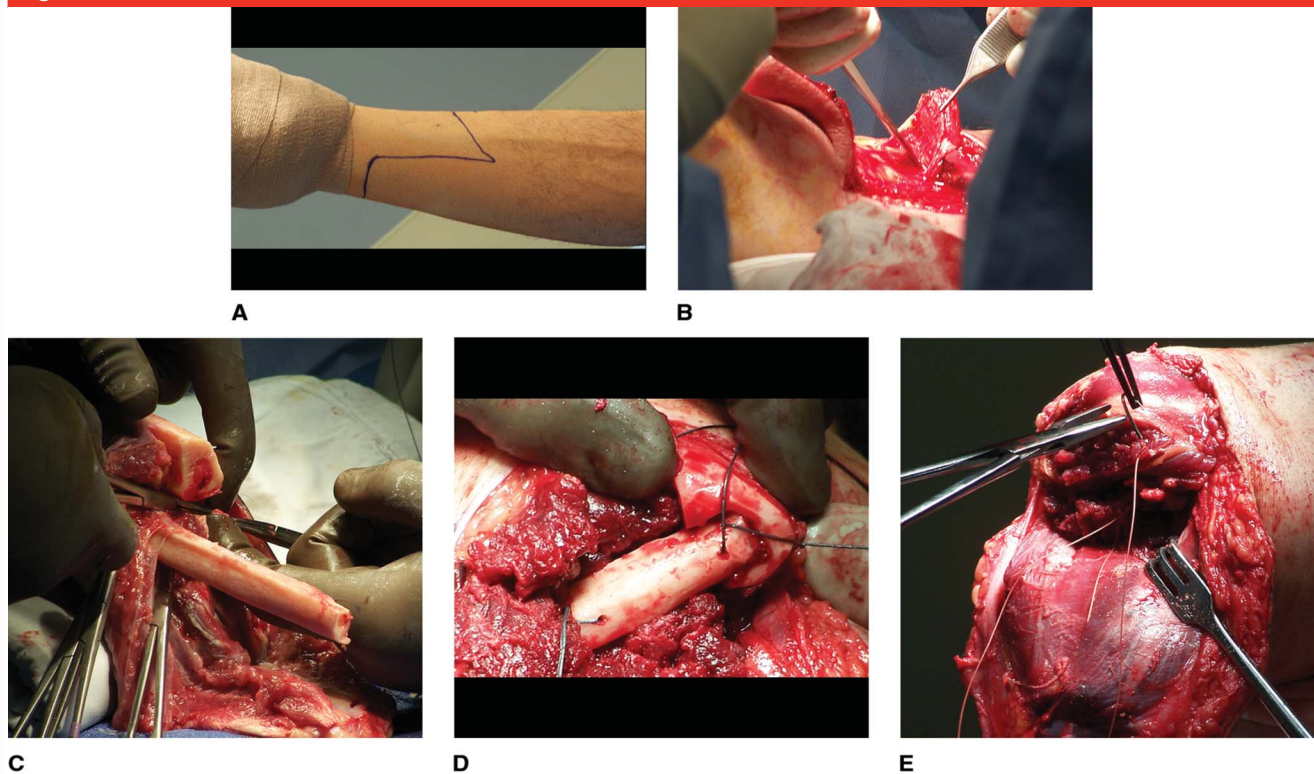
The site for the tibial incision is identified and, provided that the conditions of the distal bone and soft tissue allow, an osteoperiosteal sleeve is elevated from the tibia in a distal-to-proximal direction for approximately 8 cm to a level just above the intended level of transection. The osteoperiosteal sleeve is then tagged and allowed to retract proximally for protection during tibial transection. Finally, soft tissue is elevated from the posterior tibia and the tibial cut is made with an oscillating saw. The distance between the tibia and fibula at the level of the tibial cut is then measured, and the peroneal musculature and fibula are transected at this distance distal to the level of tibial transection after ligation

and division of the neurovascular bundle in the lateral compartment.

The deep posterior compartment is transected at the level of the tibial cut, and the superficial posterior compartment is then sharply beveled from the tibial cut to the level of the skin incision for the posterior flap. The posterior neurovascular bundle is identified and carefully separated, ligated, and divided. The tibial nerve should be cut as proximally as possible, whereas the posterior tibial artery and vein should be divided as distally as possible to protect the vascularity of the posterior musculocutaneous flap. The amputated portion of the limb is then removed from the operating table; bone graft often can be harvested from the distal tibia or calcaneus to augment the bone bridge of the amputation or for other concurrent orthopaedic procedures.<sup>9</sup> The sural nerve is identified in the subcutaneous posterior flap, and the nerve is transected via a limited anterior approach.<sup>18</sup>

A second fibular osteotomy is then made at the level of the tibial cut, and the intact fibula and distal tibia are notched with a high-speed burr to create a tight-fitting space for placement of the fibular autograft (Figure 2). Once the distal tibia is shaped appropriately, eight 2.0-mm holes are drilled for suture passage: two in the medial distal tibia, two in the medial edge of the transverse fibular strut, two in the lateral edge of the transverse fibular strut, and two in the distal aspect of the intact fibula. Heavy nonabsorbable suture is used to attach the fibular strut at this time, and the osteoperiosteal flap is carried distally around the bone bridge as a vascularized sleeve and sutured into position. Autogenous bone graft can be placed on the proximal surface of the bone bridge or placed within the osteoperiosteal flap at this time. The tourniquet is then released and all bleeding points are clamped and ligated or treated via electrocautery. Once



**Figure 2**

**A**, Preoperative clinical photograph of the distal tibia demonstrating the desired incision level. The apex of the intended incision is  $<90^\circ$ . Intraoperative photographs demonstrating the elevation of the osteoperiosteal flap from the tibia with a sharp osteotome (**B**) and the remaining limb with the long fibula after amputation (**C**). Intraoperative photographs demonstrating fixation of the fibular bone bridge with heavy, nonabsorbable suture (**D**) and closure of the peroneal musculature over the distal bone bridge (**E**). Careful attention to closure and soft-tissue balancing is crucial.

careful hemostasis is obtained, the peroneal musculature is brought over the end of the strut medially and sutured into place. The fascia of the posterior musculature is then attached to the anterior tibial periosteum and the anterior compartment fascia. Subcutaneous tissue is closed in a layered fashion, and the skin edges are finally brought together in a tension-free manner with interrupted non-absorbable sutures. Any dog ears should be trimmed sparingly to minimize additional vascular insult to the surrounding skin edges.

### Postoperative Rehabilitation Protocol

At the conclusion of the procedure, the residual limb is placed into an immediate postoperative prosthesis

by a licensed prosthetist, if available, to allow for earlier mobilization, to improve psychological function, and to reduce surgical site complications (eg, dehiscence).<sup>19,20</sup> Patients are allowed to ambulate immediately, but full weight bearing is precluded until 6 to 8 weeks after surgery to allow for bony and soft-tissue healing. Initial true prosthetic socket fitting is begun as early as 4 weeks post-operatively but can be delayed in instances of delayed incisional healing or persistent wound drainage.

### Clinical Experiences and Outcomes

In the initial description of the Ertl technique, the osteoperiosteal flap was used to obtain distal tibiofibular

stability; however, full bony union is not always achievable with the flap alone.<sup>21</sup> The modified procedure involves placement of an autograft fibular segment in the bridging region as an alternative to the osteoperiosteal flap. In several studies, successful union has been reported in 86% to 100% of patients who underwent amputation with the modified Ertl technique.<sup>8,9,22</sup> In these reports, the authors note that fibular periosteal and soft-tissue attachments were maintained whenever possible to maximize the healing potential of the bony bridge. Time to union of the fibular strut was an average of 16 weeks (range, 8 to 20 weeks).

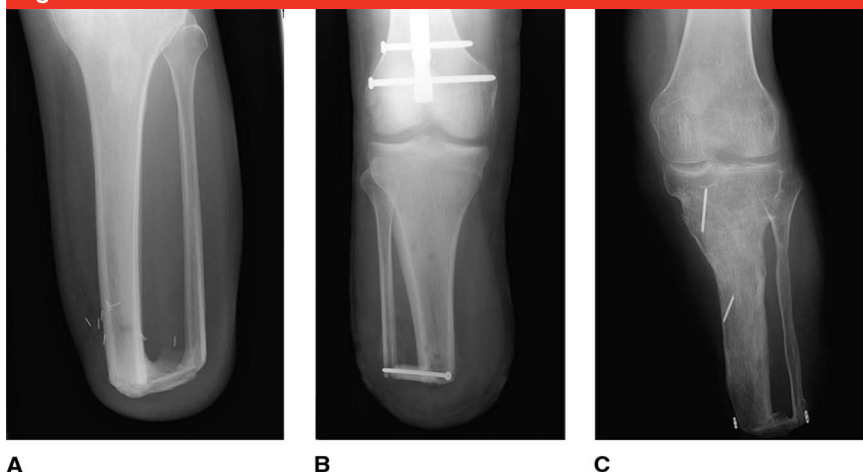
As mentioned earlier, there are several different fixation methods for the fibular strut and/or osteoperiosteal

sleeve, and consensus regarding the optimal construct is lacking at this time. In the traditional Ertl technique, the osteoperiosteal sleeve and the myoplasty are fixed with heavy non-absorbable suture. This construct allows for a stable platform, but other authors have suggested the use of a single small-fragment screw for fixation of the fibular segment, which presumably results in increased initial stability.<sup>22-26</sup> The screw is placed in a retrograde fashion from the fibular strut into the intact tibia or in a transverse fashion from the intact fibula, through the fibular strut, and into the intact medial tibial cortex.

Several authors have reported on the use of the TightRope to stabilize the fibular strut.<sup>22,27</sup> Proponents of this device note that suture breakage over the sharp edges of bone tunnels is less frequent and that the development of symptomatic implant prominence is less likely with the TightRope device than with screws. However, no comparative evidence exists to corroborate these claims (Figure 3).

Several studies have compared osteomyoplastic amputation techniques with the traditional transtibial amputation technique. Surgical time for the Ertl technique is generally longer and has been reported to be as much as twice that of the non-bone-bridging technique, with corresponding increases in tourniquet time.<sup>9,28</sup> Despite the increased surgical time, the risk of deep infection or wound complications does not appear to be elevated.<sup>9,22,23,28</sup> However, the addition of the bone bridge does add another surgical variable that has been shown to increase the incidence of complications. In fact, nonunion of the bone bridge is reported in 0% to 14% of cases in two studies, although revision is not always necessary.<sup>8,9</sup> Device irritation is the most common complication associated with the Ertl technique, and with screw fixation, implant removal rates as high as 27% have been reported.<sup>22</sup> Interestingly,

**Figure 3**



AP radiographs of a lower extremity after transtibial amputation and fixation of the fibular strut with heavy nonabsorbable suture (A), fixation with a 3.5-millimeter screw (B), and fixation with the TightRope (Arthrex) (C). At this time, no comparative evidence is available to evaluate the differences among these fixation constructs.

although one recent study noted a considerable increase in the rate of revision with the modified Ertl technique,<sup>22</sup> other studies have found no marked difference between osteomyoplastic and traditional amputation techniques with regard to the rate of revision.<sup>9,23,28</sup>

Controversy exists regarding the optimal transtibial amputation technique, with data supporting both the traditional transtibial and Ertl techniques. One study found no difference between the techniques with regard to limb-socket kinematics,<sup>26</sup> although the analysis was limited to vertical displacement of the stump with loading, which is likely an oversimplification of a complex biomechanical interaction. Advocates of the Ertl technique report that the stump better tolerates direct end bearing in a prosthesis because the increased surface area of the stump is better able to dissipate forces, resulting in less pain from the unstable pathologic motion of the remaining fibula.<sup>8,9,12,17,21,23,24,27,29</sup> In addition, although the rate of ambulation in armed forces service members who have undergone amputation with

either technique is not substantially different,<sup>22,28</sup> two civilian studies did report a considerably increased rate of ambulation with the Ertl osteomyoplastic technique, which corresponds with our clinical experience.<sup>9,23</sup> Civilian patient-reported outcomes have been investigated as well, with reports of the Ertl osteomyoplastic technique having equivalent<sup>29,30</sup> or better<sup>9,14</sup> scores in terms of function and quality of life compared with the scores in patients who underwent traditional transtibial amputation. However, many of these studies have been completed using different questionnaires, and critical comparisons of groups cannot be made.

### Future Directions

Much of the evidence supporting the Ertl technique is limited and primarily consists of level III to V evidence, with a lack of high-quality level I evidence. The US Department of Defense has acknowledged this knowledge deficit and supports the completion of a randomized, prospective study by the

Major Extremity Trauma Research Consortium to compare the traditional and Ertl types of transtibial amputations.<sup>31</sup> The knowledge gained from this investigation has the potential to be of considerable benefit to future amputees and may provide further insight into the specific indications, techniques, and protocols that would maximize function in this patient population.

## Summary

We strongly believe in the concepts of a biologic amputation surgery, with preservation of as much anatomy as possible and restoration of the physiology and structure in an attempt to limit the postoperative dysfunction that is common in many amputees. The Ertl transtibial amputation technique was originally developed and subsequently modified to achieve these goals, and despite the limited and often conflicting evidence on the technique, we believe that it remains a safe and viable option for patients requiring a transtibial amputation.

## References

**Evidence-based Medicine:** Levels of evidence are described in the table of contents. In this article, references 1 and 3 are level I studies. References 2 and 30 are level II studies. References 9, 14, 19, 22, and 28 are level III studies. References 4, 5, 8, 11-13, 15-18, 20, 21, 23-27, and 29 are level IV studies. References 7 and 10 are level V expert opinion.

References printed in **bold type** are those published within the past 5 years

1. Bosse MJ, MacKenzie EJ, Kellam JF, et al: An analysis of outcomes of reconstruction or amputation after leg-threatening injuries. *N Engl J Med* 2002;347(24):1924-1931.
2. Penn-Barwell JG: Outcomes in lower limb amputation following trauma: A systematic review and meta-analysis. *Injury* 2011;42(12):1474-1479.
3. MacKenzie EJ, Bosse MJ, Castillo RC, et al: Functional outcomes following trauma-related lower-extremity amputation. *J Bone Joint Surg Am* 2004;86(8):1636-1645.
4. Ertl J: Uber Amputationstumpfe. *Chirurg* 1949;20:218-224.
5. Mongon ML, Piva FA, Mistro Neto S, Carvalho JA, Belangero WD, Livani B: Cortical tibial osteoperiosteal flap technique to achieve bony bridge in transtibial amputation: Experience in nine adult patients. *Strategies Trauma Limb Reconstr* 2013;8(1):37-42.
6. Condie DN: Electromyography of the lower limb amputee, in Cerquiglini S, Venerando A, Wartenweiler J, eds: *Medicine and Sport Biomechanics III*. Basel, Switzerland, Karger, 1973, vol 8, pp 65-72.
7. Hansen-Leth C, Reimann I: Amputations with and without myoplasty on rabbits with special reference to the vascularization. *Acta Orthop Scand* 1972;43(1):68-77.
8. Pinto MA, Harris WW: Fibular segment bone bridging in trans-tibial amputation. *Prosthet Orthot Int* 2004;28(3):220-224.
9. Taylor BC, French B, Poka A, Blint A, Mehta S: Osteomyoplastic and traditional transtibial amputations in the trauma patient: Perioperative comparisons and outcomes. *Orthopedics* 2010;33(6):390.
10. Hansen-Leth C: Muscle blood flow after amputation with special reference to the influence of osseous plugging of the medullary cavity: Assessed by 133 xenon and histamine. An animal experiment. *Acta Orthop Scand* 1976;47(6):613-618.
11. Malloy JP, Dalling JG, El Dafrawy MH, Bustillo JS, Reid JS: Tibiofibular bone-bridging osteoplasty in transtibial amputation: Case report and description of technique. *J Surg Orthop Adv* 2012;21(4):270-274.
12. DeCoster TA, Hamedan S: Amputation osteoplasty. *Iowa Orthop J* 2006;26:54-59.
13. Berlet GC, Pokabla C, Serynek P: An alternative technique for the Ertl osteomyoplasty. *Foot Ankle Int* 2009;30(5):443-446.
14. Pinzur MS, Pinto MA, Saltzman M, Batista F, Gottschalk F, Juknelis D: Health-related quality of life in patients with transtibial amputation and reconstruction with bone bridging of the distal tibia and fibula. *Foot Ankle Int* 2006;27(11):907-912.
15. Pinzur MS, Stuck RM, Sage R, Hunt N, Rabinovich Z: Syme ankle disarticulation in patients with diabetes. *J Bone Joint Surg Am* 2003;85(9):1667-1672.
16. Williams RM, Turner AP, Norvell DC, Henderson AW, Hakimi KN, Czerniecki JM: The role of expectations in pain after dysvascular lower extremity amputation. *Rehabil Psychol* 2014;59(4):459-463.
17. Taylor BC, Poka A: Osteomyoplastic transtibial amputation: Technique and tips. *J Orthop Surg Res* 2011;6:13.
18. Tintle SM, Donohue MA, Shawen S, Forsberg JA, Potter BK: Proximal sural traction neurectomy during transtibial amputations. *J Orthop Trauma* 2012;26(2):123-126.
19. Ali MM, Loretz L, Shea A, et al: A contemporary comparative analysis of immediate postoperative prosthesis placement following below-knee amputation. *Ann Vasc Surg* 2013;27(8):1146-1153.
20. Folsom D, King T, Rubin JR: Lower-extremity amputation with immediate postoperative prosthetic placement. *Am J Surg* 1992;164(4):320-322.
21. Okamoto AM, Guarniero R, Coelho RF, Coelho FF, Pedrinelli A: The use of bone bridges in transtibial amputations. *Rev Hosp Clin Fac Med Sao Paulo* 2000;55(4):121-128.
22. Tintle SM, Keeling JJ, Forsberg JA, Shawen SB, Andersen RC, Potter BK: Operative complications of combat-related transtibial amputations: A comparison of the modified burgess and modified Ertl tibiofibular synostosis techniques. *J Bone Joint Surg Am* 2011;93(11):1016-1021.
23. Brown BJ, Iorio ML, Hill L, et al: Ertl below-knee amputation using a vascularized fibular strut in a nontrauma elderly population: A case series. *Ann Plast Surg* 2014;73(2):196-201.
24. Mongon ML, Piva FA, Mistro Neto S, Carvalho JA, Belangero WD, Livani B: Cortical tibial osteoperiosteal flap technique to achieve bony bridge in transtibial amputation: Experience in nine adult patients. *Strategies Trauma Limb Reconstr* 2013;8(1):37-42.
25. Malloy JP, Dalling JG, El Dafrawy MH, Bustillo JS, Reid JS: Tibiofibular bone-bridging osteoplasty in transtibial amputation: Case report and description of technique. *J Surg Orthop Adv* 2012;21(4):270-274.
26. Tucker CJ, Wilken JM, Stinner PD, Kirk KL: A comparison of limb-socket kinematics of bone-bridging and non-bone-bridging wartime transtibial amputations. *J Bone Joint Surg Am* 2012;94(10):924-930.
27. Ng VY, Berlet GC: Improving function in transtibial amputation: The distal tibiofibular bone-bridge with Arthrex Tightrope fixation. *Am J Orthop (Belle Mead NJ)* 2011;40(4):E57-E60.
28. Gwinn DE, Keeling J, Froehner JW, McGuigan FX, Andersen R: Perioperative

- 
- differences between bone bridging and non-bone bridging transtibial amputations for wartime lower extremity trauma. *Foot Ankle Int* 2008;29(8):787-793.
29. Pinzur MS, Beck J, Himes R, Callaci J: Distal tibiofibular bone-bridging in transtibial amputation. *J Bone Joint Surg Am* 2008;90(12):2682-2687.
30. Keeling JJ, Shawen SB, Forsberg JA, et al: **Comparison of functional outcomes following bridge synostosis with non-bone-bridging transtibial combat-related amputations.** *J Bone Joint Surg Am* 2013; 95(10):888-893.
31. Major Extremity Trauma Research Consortium: TAOS/Ertl study. <https://metrc.org>. Accessed January 11, 2016.